

**ORIGINAL RESEARCH**

# Metrical analysis of coronary sinus in human heart

<sup>1</sup>Dr. Manish Kumar, <sup>2</sup>Dr. Babita Priti, <sup>3</sup>Dr. Amresh Kumar, <sup>4</sup>Dr. Rakesh Ranjan

<sup>1</sup>Tutor, Department of Anatomy, JNKTMCH Madhepura, Bihar, India

<sup>2</sup>Tutor, <sup>4</sup>Assistant Professor & HOD, Department of Anatomy, GMCH Purnea, Bihar, India

<sup>3</sup>Medical Officer, Department of Anatomy, Village & Post –Sori District –Aurangabad P. S - Mali Bihar, India

**Corresponding Author**

Dr. Babita Priti

Tutor, Department of Anatomy, GMCH Purnea, Bihar, India

Received: 15 April, 2024

Accepted: 18 May, 2024

**ABSTRACT**

**Background:** A dilated venous channel called the coronary sinus drains blood from the majority of the heart. The present study performed metrical analysis of coronary sinus in human heart. **Materials & Methods:** 54 human cadaveric hearts were retrieved. The coronary sinus was measured for length and width at three different locations: its formation site (where the GCV joins the proximal designated tributary), its middle location (where the MCV enters the CS), and its termination point near the RA. A digital vernier caliper was used for these measurements. **Results:** GCV with LMV was present in 40 and absent in 14, GCV with PVLV was present in 12 and GCV with OVLA was present in 2 cases. The difference was significant ( $P < 0.05$ ). The length of CS GCV with LMV was 57.2 mm, GCV with PVLV was 56.8 mm and GCV with OVLA was 20.3 mm. The difference was significant ( $P < 0.05$ ). The valve of CS was present in 39 and absent in 15 cases. **Conclusion:** The formation of the coronal sinus varied among 54 human hearts that were kept in formalin. The Coronary sinus opening in the right atrium is primarily oval in shape and is protected by a semicircular valve. **Keywords:** coronary sinus, cadaveric hearts, right atrium.

---

This is an open access journal, and articles are distributed under the terms of the Creative Commons Attribution- Non commercial-Share Alike 4.0 License, which allows others to remix, tweak, and build upon the work non-commercially, as long as appropriate credit is given and the new creations are licensed under the identical terms.

---

**INTRODUCTION**

A dilated venous channel called the coronary sinus drains blood from the majority of the heart. It opens into the right atrium and is located in the posterior coronary sulcus. Its narrow width and length are the source of the name sinus.<sup>1</sup> The coronary sinus has been understood since ancient times. For ages, the earliest anatomists, like Eristratos (280 BC) and Galeno (129 AD), believed that it was a vein that returned blood to the heart. It opens into the right atrium between the tricuspid orifice and the inferior vena cava aperture, and it typically receives five major tributaries.<sup>2</sup> The coronary sinus, located in the posterior coronary sulcus (atrioventricular groove), is a broad venous conduit that is roughly 2 to 3 cm long. It typically starts at the left end of the posterior coronary sulcus, where the left marginal vein or veins from the left ventricle unite with the major cardiac vein. It then travels towards the right, terminating in the right atrium. A valve known as the Thebasian valve, a remnant of the right venous valve of the sinus venosus, guards the aperture.<sup>3</sup>

The large cardiac vein, left marginal vein, veins from the left ventricle, left atrial oblique vein, middle cardiac vein, and small cardiac vein are the typical designated tributaries.<sup>4</sup> It can occasionally be partially hidden by myocardial fibers in the posterior coronary sulcus, where it extends deep to the epicardium. The anterior region of the right ventricle is drained by the anterior cardiac veins.<sup>5</sup> They climb in subepicardial tissue to cross the right portion of the anterior-atrioventricular sulcus, usually in groups of two or three, but occasionally in groups of five. From there, they might pass superficially or deeply to the right coronary artery. Either alone or in varying combinations, they terminate in the right atrium's anterior wall, close to the sulcus.<sup>6</sup> The present study performed metrical analysis of coronary sinus in human heart.

**MATERIALS & METHODS**

The present study was conducted on 54 human cadaveric hearts in the Department of Anatomy of JNKTMCH Madhepura, Bihar, India. The study was conducted from June 2023 to December 2023.

Data such as name, age, etc. was recorded. To examine the entrance of the coronary sinus, the right atrium was opened. Next, coloring agents were injected through the CS orifice in the RA to clearly show the tributaries of the coronary sinus. The tributaries were subsequently cleaned and photographed. The coronary sinus was measured for length and width at three different locations: its formation site (where the GCV joins the proximal

designated tributary), its middle location (where the MCV enters the CS), and its termination point near the RA. A digital verniercaliper was used for these measurements. The geometry of the CS valve was observed and photographed, and the orifice of the CS was measured using a DigitalVerniercaliper. Data thus obtained were subjected to statistical analysis. P value < 0.05 was considered significant.

**RESULTS**

**Table I: Formation of Coronary sinus**

Parameters	Present	Absent	P value
GCV WITH LMV	40	14	0.05
GCV WITH PVLV	12	-	
GCV WITH OVLA	2	-	

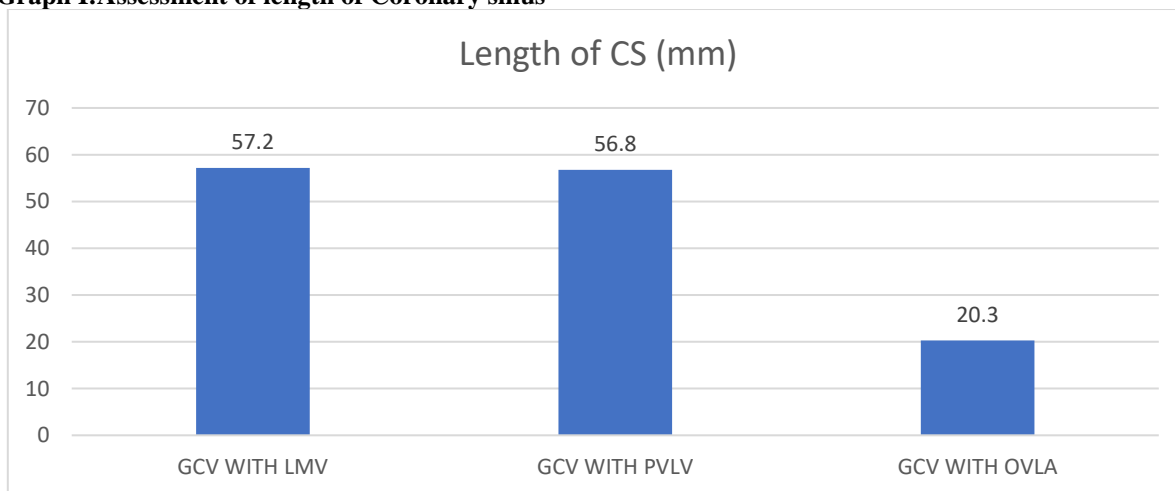
Table I shows that GCV with LMV was present in 40 and absent in 14, GCV with PVLV was present in 12 and GCV with OVLA was present in 2 cases. The difference was significant (P< 0.05).

**Table II: Assessment of length of Coronary sinus**

Formation of CS	Length of CS(mm)	P value
GCV WITH LMV	57.2	0.05
GCV WITH PVLV	56.8	
GCV WITH OVLA	20.3	

Table II shows that length of CS GCV with LMV was 57.2mm, GCV with PVLV was 56.8 mm and GCV with OVLA was 20.3 mm. The difference was significant (P< 0.05).

**Graph I:Assessment of length of Coronary sinus**



**Table III Valve of coronary sinus**

	Present	Absent
Valve of CS	39	15

Table III shows that valve of CS was present in 39 and absent in 15 cases.

**DISCUSSION**

The coronary sinus is a large vein located on the posterior aspect of the heart, which collects deoxygenated blood from the myocardium (heart muscle) and delivers it to the right atrium.<sup>7</sup> It plays a crucial role in the coronary circulation system, which supplies blood to the heart muscle itself.<sup>8</sup>The coronary sinus is situated in the coronary sulcus, a groove on the heart's posterior surface, between the left atrium

and the left ventricle.<sup>9</sup>It is a short, wide venous channel, about 2-3 cm in length, and is the main venous drainage vessel of the heart.The coronary sinus opens into the right atrium, near the inferior vena cava opening.<sup>10,11</sup>The present study performed metrical analysis of coronary sinus in human heart.

We found that GCV with LMV was present in 40 and absent in 14, GCV with PVLV was present in 12 and GCV with OVLA was present in 2 cases. Das et al<sup>12</sup>in their study the gross anatomy and metrical analysis

was carried out in 60 human hearts taken from the cadavers (irrespective of sex and age). The morphological features of coronary sinus were investigated along with study of its metrical analysis. The formation, course, variation in its tributaries and termination to the right atrium were investigated and recorded. The study of Coronary sinus utilizing 60 human hearts (irrespective of age and sex) preserved in formalin showed variations in its formation. The orifice of the Coronary sinus in the right atrium appeared mostly oval in shape and is guarded by semi lunar shaped valve in 59 of specimens and semicircular in one specimen.

We observed that the length of CS GCV with LMV was 57.2 mm, GCV with PVLV was 56.8 mm and GCV with OVLA was 20.3 mm. Zabina et al<sup>13</sup> studied the location, shape, length and width of CS including its left atrial muscular coverage in 50 cadaveric hearts. Location and shape of CS were noted, external and internal lengths of the CS were measured with the help of a thread and Vernier caliper. Width of CS was measured at three levels; at the beginning, at the point of entry of Middle Cardiac Vein (MCV) and at termination in right atrium. The walls of CS were examined to note whether they were covered by the muscles of left atrium or not. CS was located in the posterior atrioventricular sulcus in 98%. Two shapes; funnel in 82% and tubular/cylindrical in 18% were observed. External length of coronary sinus ranged from 20.5 mm to 58.78 mm (mean 38.22±8.6 mm) and internal length ranged from 16.28 mm to 49.6 mm (mean 34.48±8.9 mm). Maximum width of coronary sinus was at its termination (9.61±2.6 mm) and it was covered by muscles of left atrium in 96% of hearts.

We found that the valve of CS was present in 39 and absent in 15 cases. Ankolekar et al<sup>14</sup> studied the anatomy of the coronary venous system and its tributaries in cadaveric hearts. Length of coronary sinus (CS) ranged from 2cm to 3.8cm, the mean being 2.8cm. Relation of coronary sinus to the left coronary artery (LCA) and mitral valve annulus was above and parallel in 100% cases. The number of Atrial tributaries ranged from 1-2 and ventricular from 1-6. d. The mean distance of Anterior interventricular vein (AIV), Posterior vein of the left ventricle (PVLV), Oblique vein of left atrium (OVLA), Middle cardiac vein (MCV) from the coronary ostium was 67.5mm, 32mm, 41mm, 7mm respectively. The average length and width of coronary ostium was 9mm and 13mm respectively. The besian valve in 24/55 hearts was attached to the superior, right and inferior margins of the ostium. In 29/55 hearts to the inferior margin of the ostium. The shortcoming of the study is small sample size.

## CONCLUSION

Authors found that the formation of the coronal sinus varied among 54 human hearts that were kept in formalin. The Coronary sinus opening in the right

atrium is primarily oval in shape and is protected by a semicircular valve.

## REFERENCES

- Alonso C, Leclercq C, d'Allonnes FR, Pavin D, Victor F, Mabo P et al. Six- year experience of transvenous left ventricular lead implantation for Permanent biventricular pacing in patients with advanced heart failure: technical aspects'. *Heart*. 2001; 86: 405-10.
- Ortale JR, Gabriel EA, Iost C, Márquez CQ, The anatomy of the coronary sinus and its tributaries. *Surg. Radiol. Anat.* 2001; 23(1):15-21.
- Habib A, Lachman N, Christensen KN, Asirvatham SJ. The anatomy of the coronary sinus venous system for the cardiac electrophysiologist. *Europace*. 2009; 11 Suppl 5: v15-v21.
- Iyer PB. Great cardiac vein draining directly into the right atrium – A case report. *J. Anat. Soc. India*. 2006; 55: 60-64.
- Olearczyk BM, Menzies DJ, McNulty PH. Anomalous great cardiac vein. *J. Card. Surg.* 2008; 23: 408-409.
- Aherman K. & J. Lowell, Anatomic Variations of the Orifice of the Human Coronary Sinus: *J. of A.H.A., Cir.* 1951 ; 3 : 514-523.
- Kim SY, Hong YJ, Lee HJ, Hur J, Choi BW, Kim YJ. Anomalous great cardiac vein draining into the right atrium combined with a single left coronary artery. *Int. J. Cardiovasc. Imaging*. DOI: 10.1007/s10554-013-01959.
- Kargoz A, Ucar O, Kutucularoglu MG, Vural M, Diker E. Multidetector computed tomographic anatomy of the coronary sinus in patients with supraventricular reentrant tachycardia. *Kardiol Pol.* 2013; 71(9):911-16.
- Lee MS, Atman PS, Ninh D, Daniel B, James F, Prediman KS, et al. Coronary sinus is dilated and outwardly displaced in patients with mitral regurgitation. *Catheterization and Cardiovascular Interventions*. 2006; 67:490-94.
- Plass A, Valenta I, Gaemperli O, Kauffmann P, Alkadhi H, Zund G, et al. Assessment of coronary sinus anatomy between normal and insufficient mitral valves by multi-slice computed tomography for mitral annuloplasty device implantation. *Eur J Crdiothorac Surg.* 2008; 33:583-89.
- Habib A, Lachman A, Christensen KN, Asirvatham S. The anatomy of the coronary sinus venous system for the cardiac electrophysiologist. *Europace*. 2009; 11(5):15-21.
- Prerna Das, Mrinalini Sinha, Birendra Kumar Sinha, Vivekanand. Study of Gross Anatomy and Metrical Analysis of Coronary Sinus in Human Heart. *European Journal of Molecular & Clinical Medicine (EJMCM)* 2023; 648- 654.
- Zabina B, Singla RK, Sharma RK, Bala N. Morphological and morphometric study of coronary sinus in north Indian population. *Journal of Clinical and Diagnostic Research: JCDR.* 2017 Sep; 11(9):AC15.
- Ankolekar VH, Quadros LS, D'souza AS. Morphometric and morphological variations of coronary venous system and its tributaries - An anatomical study. *J Pharm Biomed Sci.* 2013; 34(34):1663-69.