

ORIGINAL RESEARCH

To evaluate the clinical types of hypopigmented macules at tertiary care center

¹Dr. Harish Sharma, ²Dr. Aditi Sharma

¹Assistant Professor, Department of Skin, Government Medical College, Banswara, Rajasthan, India

²Third Year Resident, Department of Paediatric, Rama Medical College, Kanpur, Uttar Pradesh, India

Corresponding author

Dr. Aditi Sharma

Third Year Resident, Department of Paediatric, Rama Medical College, Kanpur, Uttar Pradesh, India

Received Date: 06 July, 2024

Accepted Date: 10 August, 2024

ABSTRACT

Aim: To evaluate the clinical types of hypopigmented macules at tertiary care center. **Materials and method:** All male and female patients between 1 - 60 years of age with hypopigmented macules attending the out-patient clinic of the Department of Dermatology, Venereology and Leprosy in Sardar Patel Medical College And PBM Group of Hospitals, Bikaner after obtaining approval from institutional ethical committee were considered for the study. Written Consent was taken from the individual patients to include them in the study. Simple random sampling was used. Prevalance of hypopigmented macules was taken as 1 out of every 20 people. **Results:** Among 100 cases of hypopigmentary disorders, vitiligo (in evolution) was seen in 21% cases, achromic pityriasis versicolor in 19% cases, pityriasis alba in 15% cases, idiopathic guttate hypomelanosis in 16% cases, post inflammatory hypopigmentation in 11% cases, leprosy in 7% cases, progressive macular hypomelanosis in 4% cases, Nevus depigmentosus in 3% cases, Nevus anemicus in 2% cases and extra genital LSA in 2% cases. **Conclusion:** Based on this study, specific dermatoscopic characteristics were identified for certain hypopigmented macular disorders. However, some dermatoscopic findings in these conditions were found to be non-specific.

Keywords: Hypopigmentary disorders, Vitiligo, Achromic Pityriasis, Nevus depigmentosus

This is an open access journal, and articles are distributed under the terms of the Creative Commons Attribution-Non Commercial-Share Alike 4.0 License, which allows others to remix, tweak, and build upon the work non-commercially, as long as appropriate credit is given and the new creations are licensed under the identical terms.

INTRODUCTION

Hypopigmented macules encompass a broad spectrum of conditions, representing a prevalent dermatological concern. These macules manifest as areas of skin with reduced pigmentation, exhibiting noticeably lighter melanin levels compared to surrounding normal skin in the same individual.¹ The prevalence of various hypopigmented conditions varies depending on factors such as patient's demographics (including age, sex, and race), geographical location, familial predisposition, and environmental exposures.² This study was aimed to investigate the utility of dermatoscopy in facilitating clinical diagnosis of select hypopigmented macules. The patient cohort comprised individuals diagnosed with conditions including vitiligo (in evolution), Pityriasis alba, Achromic pityriasis versicolor, Idiopathic guttate hypomelanosis, Indeterminate leprosy, Progressive macular hypomelanosis, Naevus anemicus, Naevus depigmentosus, Post-inflammatory hypopigmentation, and Extragenital lichen sclerosus. Despite the diverse array of conditions within this group, these share common clinical features, contributing to diagnostic

and therapeutic challenges. Notably, hypopigmented lesions are particularly conspicuous in individuals with darker skin tones, such as those of Indian ethnicity, potentially leading to significant psychological and social ramifications including depression, anxiety, and diminished self-esteem. The diagnosis of type of hypopigmented macules can be made clinically which could be further supported by various diagnostic tools, among them, one is dermatoscope. Our study is one of its kind, aimed at distinguishing various types of hypopigmented macules through the application of dermatoscopy. This pioneering effort seeks to foster a deeper comprehension, empowering clinicians to provide more informed guidance to patients and their caregivers regarding the underlying conditions. Additionally, this enhanced understanding enables better anticipation of prognostic outcomes, facilitating the development of tailored therapeutic strategies.

MATERIALS AND METHOD

A cross sectional observational study was conducted in the department of Dermatology, Venereology and

Leprosy, Sardar Patel Medical College & PBM Group of Hospitals Bikaner, Rajasthan from January 2023-December 2023 after ethical clearance onwards till desired sample size was reached for data collection. All male and female patients between 1 - 60 years of age with hypopigmented macules attending the out-patient clinic of the Department of Dermatology, Venereology and Leprosy in Sardar Patel Medical College And PBM Group of Hospitals, Bikaner after obtaining approval from institutional ethical committee were considered for the study. Written Consent was taken from the individual patients to include them in the study. Simple random sampling was used. Prevalance of hypopigmented macules was taken as 1 out of every 20 people.?

Those who give informed consent, clinically diagnosed cases of hypopigmented macules and patients between 0 -70 years of age were included in the study. Those patients who did not give consent and those who were on treatment were excluded from this study. All the new patients of hypopigmented macules between 0 -70 years of age group , irrespective of their sex reported in OPD were diagnosed after detailed and infomed consent and relevant history and clinical examination .All of the cases which were on treatment were excluded from the study. Dermatoscopic findings of hypopigmented macules were noted using handheld dermatoscope (Dermlite,

3rd generation, x10 magnification) under the supervision of guide. The digital images were captured using mobile camera. The images were studied on the computer screen and after analysis of all the images, interpretation of dermatoscopic findings were made and recorded .Interpretation of dermatoscopy was based on pattern described in literature. All participants were examined after signing of informed consent for dermatoscopic examination, photography and inclusion in study.

A detailed history of the patient including age, sex, address, education, occupation; duration were recorded and those who were on treatment for the same disease and who did not give consent for the procedure and photographs were excluded from the study . History and Clinical naked eye examination were included to record the colour, distribution and its pattern of involvement. Dermatoscopic examination was carried out in the presence of my guide.

STATISTICAL ANALYSIS

To collect required necessary information from eligible patients a pre-structured pre-tested Proforma was used. For data analysis Microsoft excel and statistical software SPSS will be used and data was analyzed with the help of frequencies, figures, proportions, measures of central tendency, appropriate statistical test

RESULTS

A total of 100 patients with hypopigmented lesions were included in the study.

Table 1: Age distribution of patients

Age in years	Number of patients
≤ 10 years	6
11-20 yrs	22
21-30 yrs	23
31-40yrs	19
41-50 yrs	13
51-60 yrs	12
>60 years	5
Total	100
Mean age (in years)	
Males	30.72 ±14.78
Females	33.94 ±16.54
Total	32.33 ± 15.76

In our study a total of 100 patients of various hypopigmentary disorders were included ranging from 0 years to 70 years. On the basis of their age, patients were divided into five groups with a class interval of 10 years each. Patients below 10 years and more than 60 years were kept in another groups, thus forming a total of six age groups. Majority of patients were between 21-30 years age group with 23% cases,

followed by 22% cases between 11-20 years, 19% cases between 31-40 years, 12% cases in 51-60 years age group, 6% were below 10 years of age and 5% above 60 years of age. The overall mean age of our study group was 32.33 yrs with a standard deviation of 15.76 years. The Mean age of Male patients was 30.72±14.78 years while that of female patients was 33.94 ±16.54 years.

Table 2: Gender distribution of cases

Gender	Number of patients
Males	50
Females	50
Total	100

Out of 100 patients included in the study, 50 (50%) were male and 50 (50%) were females.

Table 3: Clinical diagnosis

Clinical Diagnosis	No. of cases
Vitiligo (in evolution)	21
Achromic pityriasis Versicolor	19
Pityriasis alba	15
Nevus depigmentosus	3
Nevus anemicus	2
Leprosy	7
Idiopathic guttate hypomelanosis	16
Post inflammatory hyperpigmentation	11
Progressive macular hypomelanosis	4
Extra genital LSA	2
Total	100

Among 100 cases of hypopigmentary disorders, vitiligo (in evolution) was seen in 21% cases, achromic pityriasis versicolor in 19% cases, pityriasis alba in 15% cases, idiopathic guttate hypomelanosis in 16% cases, post inflammatory hypopigmentation in 11% cases, leprosy in 7% cases, progressive macular hypomelanosis in 4% cases, Nevus depigmentosus in 3% cases, Nevus anemicus in 2% cases and extra genital LSA in 2% cases.

Table 4: Dermatoscopic findings

Dermatoscopic features	No. of cases
Vitiligo (in evolution)	
Absent pigment network	9
Reduced pigment network	12
Reverse pigment network	4
Well defined margins	8
Ill defined margins	7
Nebuloid margins	2
Petaloid margins	2
Feathery margins	4
Trichrome margins	2
Satellite lesions	2
Micro koebnerization	2
Comet tail appearance	1
Sago grain appearance	1
Diffuse white glow	7
Perifollicular pigmentation	6
Perifollicular depigmentation	4
Leukotrichia	3
Perilesional pigmentation	4
Pityriasis versicolor	
Hypopigmented structure less area	19
Reduced pigment network	12
Well defined borders	14
Ill defined borders	7
Marginal hyperpigmentation/ contrast halo sign	3
Perifollicular white scales	13
White scales along furrows	7
Pityriasis alba	
Ill defined borders	8
Well defined borders	7
Brownish white background	15

Reduced pigment network	12
Focal white scales	13
Idiopathic guttate hypomelanosis	
Homogenous white background	16
Residual pigment network	6
Amoeboid margins	7
Feathery margins	6
Petaloid margins	2
Nebuloid margins	1
Post inflammatory hypopigmentation	
Decreased pigment network	11
White glow	2
White structure less area	3
Pinkish white background	6
Telangiectasia	6
Dotted vessels	3
Irregular margins	4
Regular margins	7
Leprosy	
Distorted pigment network	7
Reduced eccrine and follicular openings	6
Focal white areas	4
Diffuse white scales	2
Orange yellow background	3
Brownish white Background	4
Well defined margins	5
Ill defined margins	2
Progressive macular Hypomelanosis	
Diffuse white areas	4
Reduced pigment network	4
Illdefined margins	4
Minimal scaling	2
Nevus depigmentosus	
Uniform white background	3
Decreased pigment network	3
Irregular serrated borders	3
Nevus anemicus	
Normal pigmentary network	2
Focal areas of decreased vasculature	2
Pale brownish white background	2
Extra genital lichen sclerosus et atrophicus	
White structureless areas	2
Well defined margins	2
Follicular plugs	1
Telangiectasia	2

A total of 21 cases of vitiligo (in evolution) were studied. Among these, 12 cases had reduced pigment network, 9 cases had absent pigment network while 4 cases had reverse pigment network. Eight cases had well defined margins while 7 cases had ill defined margins. Nebuloid and petaloid margins were seen in two cases each. Feathery margins were seen in 4 cases while trichrome border was seen in 2 cases. Satellite lesions and micro koebnerization were present in 2 cases each. A total of 21 cases of pityriasis versicolor were studied. On dermatoscopy, hypopigmented structure less area were seen in 19 cases with a

decreased pigment network in 12 cases. Well-defined borders were seen in 14 of cases while ill defined borders were seen in 7 cases. Characteristics observed on dermatoscopy were the presence of white scales within the lesions in the furrows in 7 cases along with perifollicular scaling in 13 cases. The hair inside the macule had a normal color but had perifollicular scales.

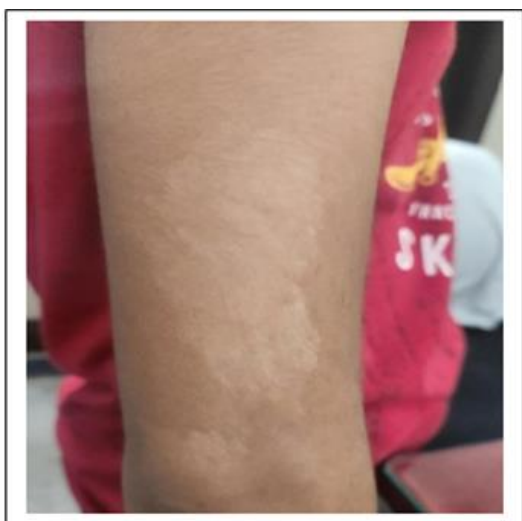A total of 15 cases of pityriasis alba were studied. On dermatoscopy, brownish white background was seen in 15 cases with a decreased pigment network in 12 cases. Well-defined borders were seen in 7 of cases

while ill defined borders were seen in 8 cases. Characteristics observed on dermatoscopy were the presence of focal white scales within the lesions in 13 cases. A total of 16 cases of idiopathic guttate hypomelanosis were studied. On dermatoscopy, homogenous white background was seen in 16 cases with a decreased pigment network in 6 cases. Amoeboid borders were seen in 7 of cases, feathery margins in 6 cases, petaloid margins in 2 cases and nebuloid margins in 1 case.

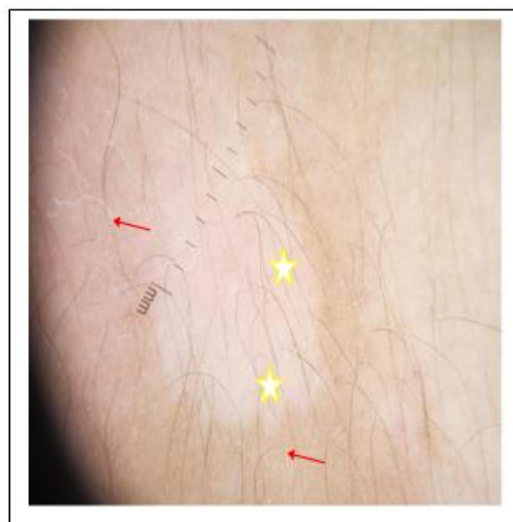
A total of 11 cases of post inflammatory hypopigmentation were studied. On dermatoscopy, homogenous white structure less area was seen in 3 cases with white glow in 2 cases while pinkish white background in 6 cases. Decreased pigment network was seen in 11 cases. Irregular borders were seen in 4 of cases and regular borders in 7 cases. Telangiectasia was observed in 6 cases while dotted vessels were seen in 3 cases. A total of 7 cases of hypopigmented patches of leprosy were studied. Among these, Orange yellow background was seen in 3 cases while brownish white background was seen in 4 cases. Focal

white areas were observed in 4 cases. Diffuse white scales were seen in 2 cases. Distorted pigment network was seen in all 7 cases while reduced eccrine and follicular openings were seen in 6 cases. Five cases had well defined margins while 2 cases had ill defined margins.

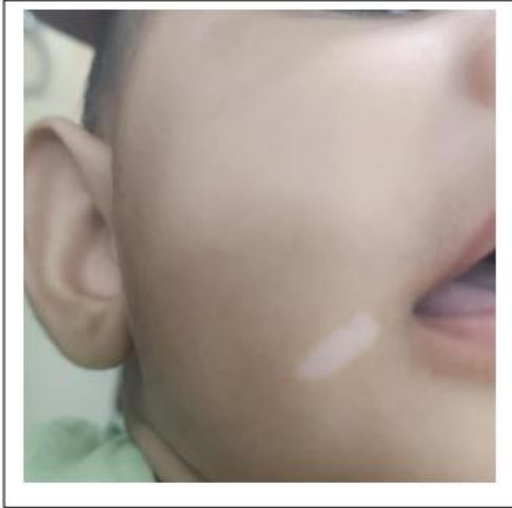A total of 4 cases of progressive macular hypomelanosis were studied. Diffuse white areas with reduced pigment network and ill defined margins were seen in all 4 cases. Minimal scaling was observed in 2 cases. Three cases of nevus depigmentosus were studied. All three cases showed uniform white background, decreased pigment network and irregular serrated borders. Two cases of nevus anemicus were studied. Both the cases showed normal pigmentary network, pale brownish white background and focal areas of decreased vasculature. Two cases of extra genital lichen sclerosus et atrophicus were studied. Both the cases showed white structureless areas with well defined margins. Telangiectasia was seen in both the cases while follicular plugging was seen in one case.



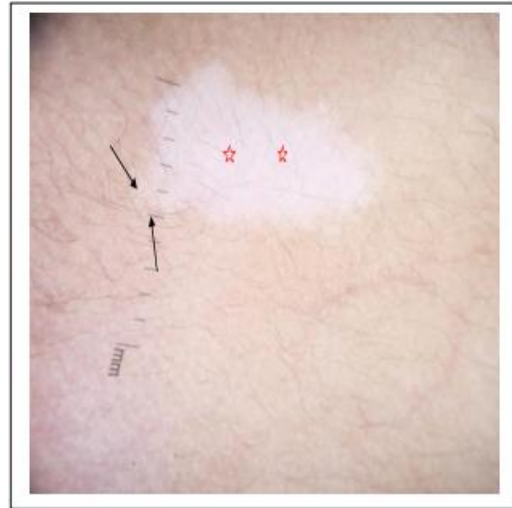**CLINICAL PICTURE OF VITILIGO
OVER RIGHT ARM**



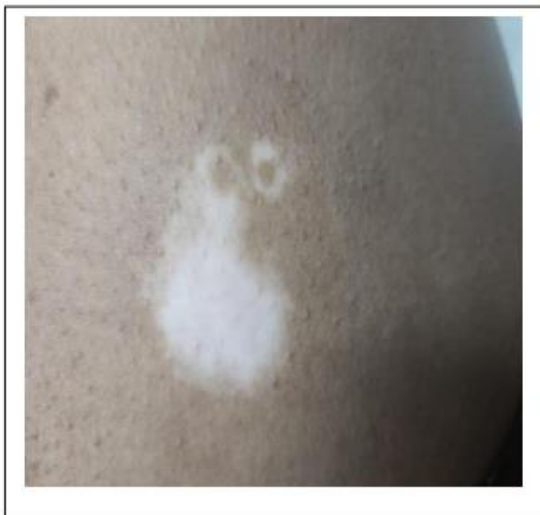**White structure less area as 'as white glow,
(yellow star) white hairs {Leucotrichia} at
some places (red arrow)**



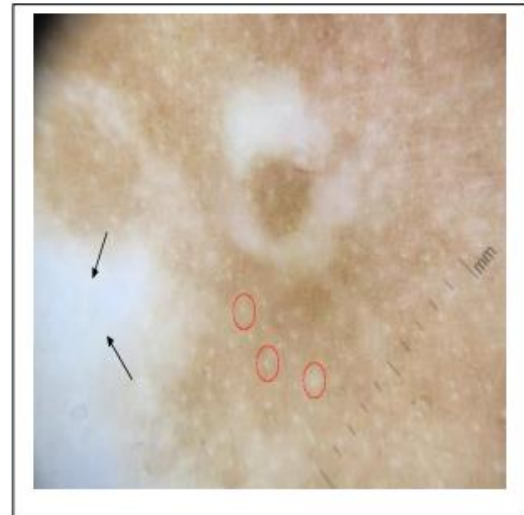
CLINICAL PICTURE OF VITILIGO NEAR ANGLE OF MOUTH



DERMATOSCOPIC PICTURE-Diffuse white glow (red star) Comet tail appearance (black arrow)




CLINICAL PICTURE OF VITILIGO OVER SHOULDER



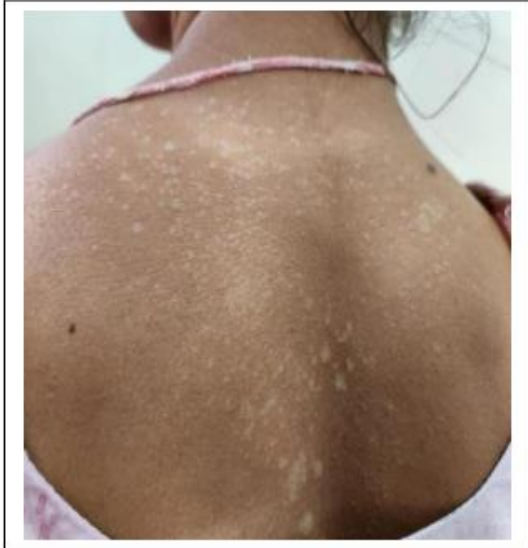Diffuse white structureless glow (black arrow) Sago grain appearance (red circle)



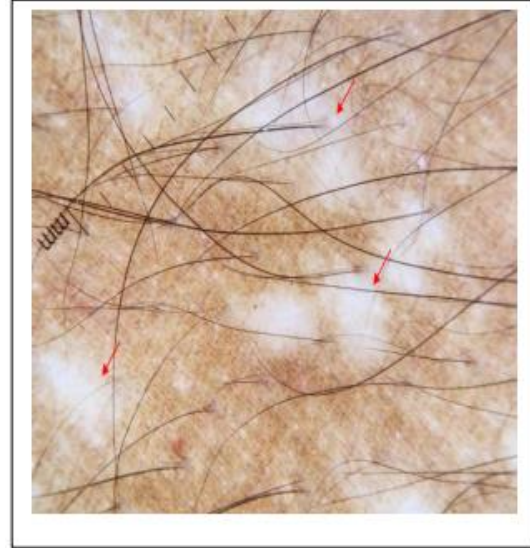
CLINICAL PICTURE OF ACHROMIC PITYRIASIS VERSICOLOR



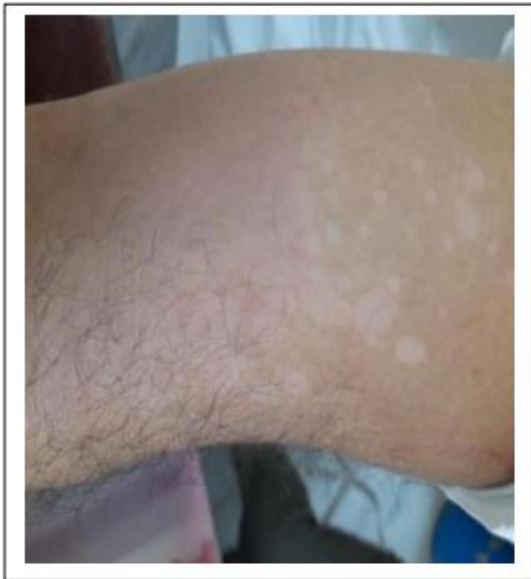Green arrow showing scales along the skin furrow




CLINICAL PICTURE OF ACHROMIC PITYRIASIS VERSICOLOR



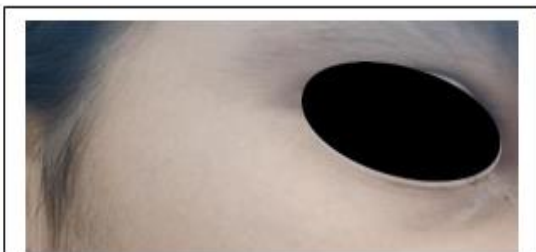
Perifollicular hypopigmentation with irregular borders (red arrow)



CLINICAL PICTURE OF ACHROMIC PITYRIASIS VERSICOLOR



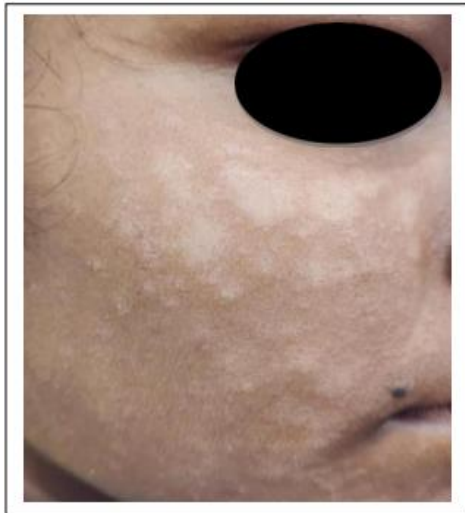
Hypopigmented structureless area with well defined borders (black arrow)



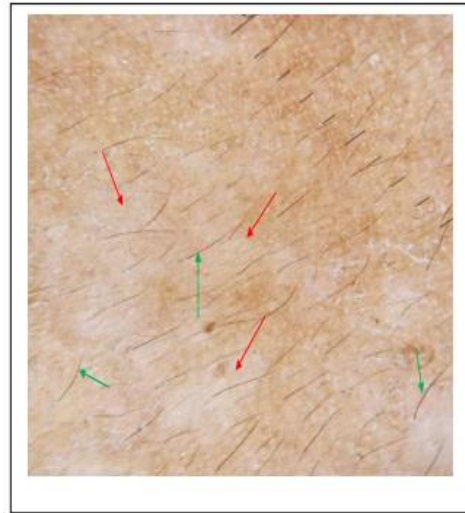CLINICAL PICTURE OF PITYRIASIS ALBA OVER CHEEK AREA



White areas with faint pigment network (green arrow) Diffuse fine white scales (red arrow)




CLINICAL PICTURE OF PITYRIASIS ALBA OVER FACE



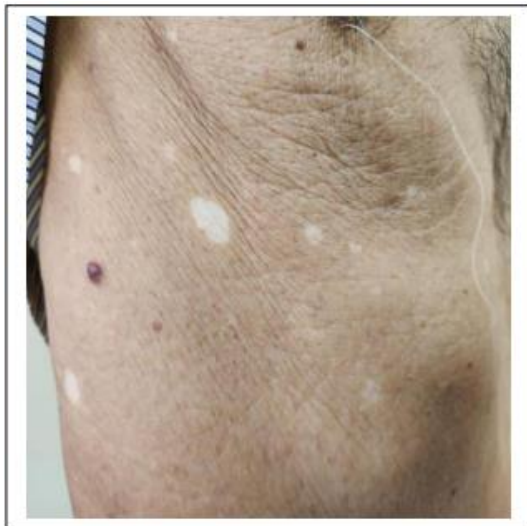Fairy ill demarcated white area with fine scales there is no sharp demarcation line between normal skin and hypopigmented areas (red arrow) Hairs are normal black in color(green arrow)



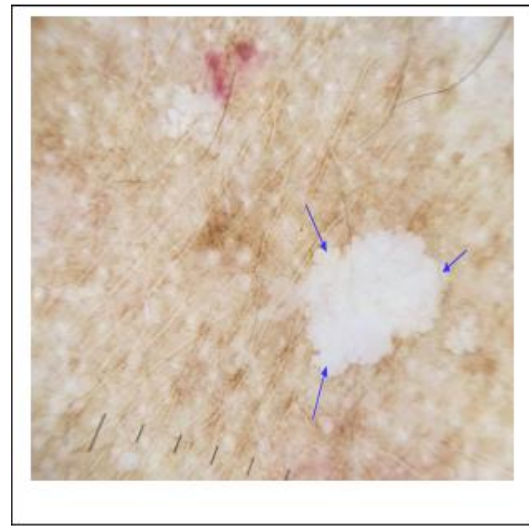
CLINICAL PICTURE OF IDIOPATHIC GUTTATE HYPOMELANOSIS OVER CHEST



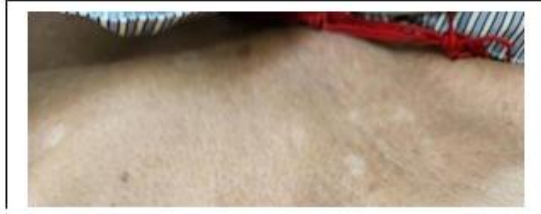(Black arrow) Well defined margins with complete loss of pigment network in amoeboid pattern with one pseudopod(yellow arrow)



CLINICAL PICTURE OF IDIOPATHIC GUTTATE HYPOMELANOSIS



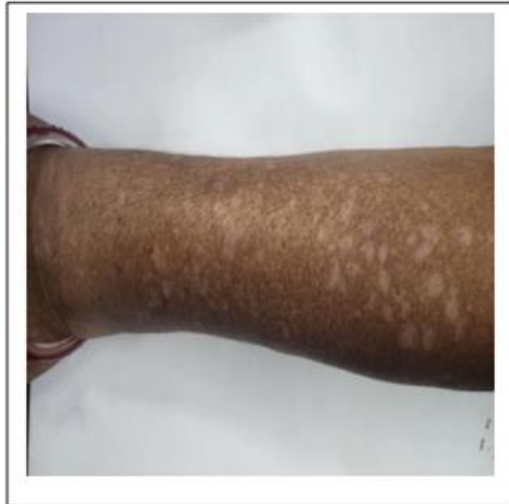(Blue arrow) Complete loss of pigment with well defined margins in petaloid pattern with leaf like extensions.



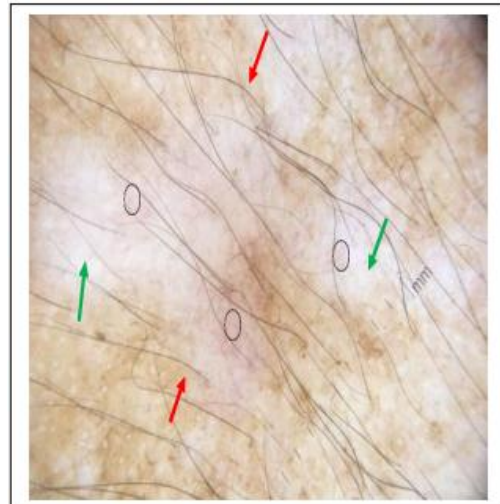
CLINICAL PICTURE OF IDIOPATHIC GUTTATE HYPOMELANOIS



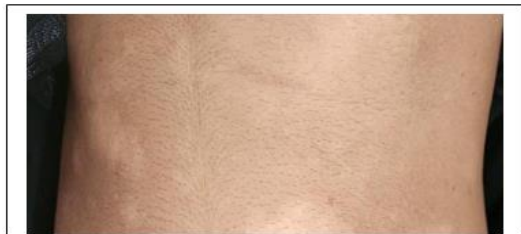(Red arrow) Hypopigmented cloudy area with residual pigment network denoted by (yellow circle)



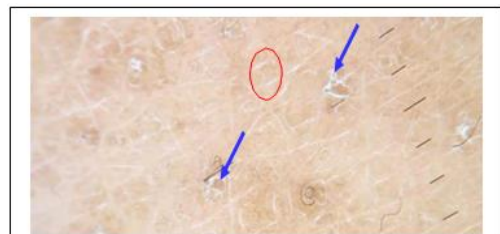CLINICAL PICTURE OF POST INFLAMMATORY HYPOPIGMENTED LESIONS OVER FOREARM



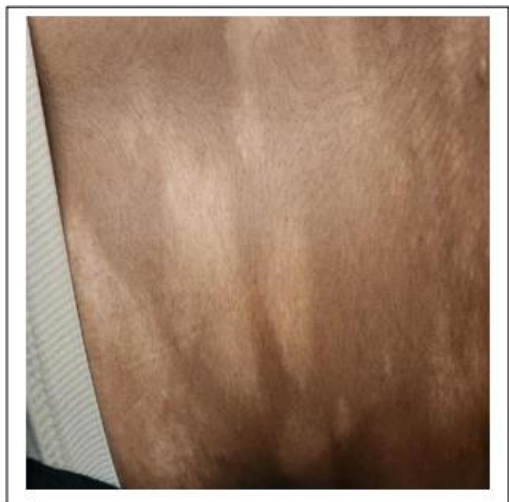
Green arrow denotes white structureless area with decreased pigment network black circle – telangiectasia, red arrow – Irregular margins

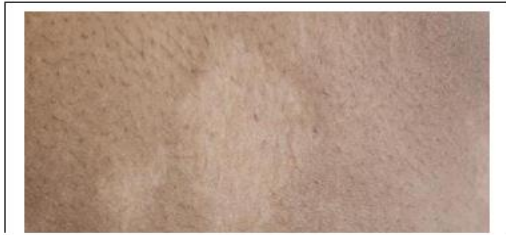

CLINICAL PICTURE OF HYPOPIGMENTED MACULES OF LEPROSY

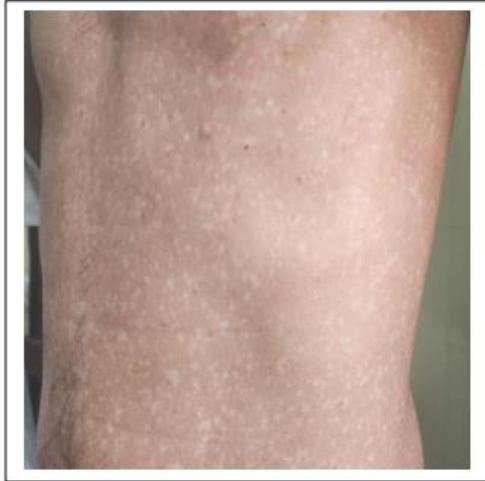


Blue arrow showing reduced eccrine and follicular openings





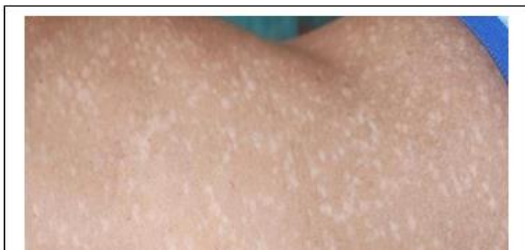CLINICAL PICTURE OF HYPOPIGMENTED MACULE OF LEPROSY



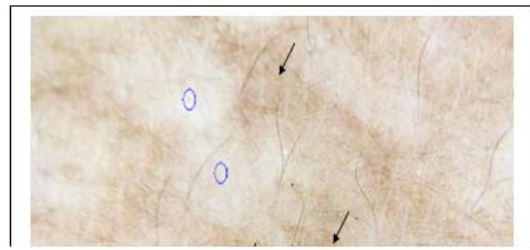
CLINICAL PICTURE OF PROGRESSIVE MACULAR HYPOMELANOSIS



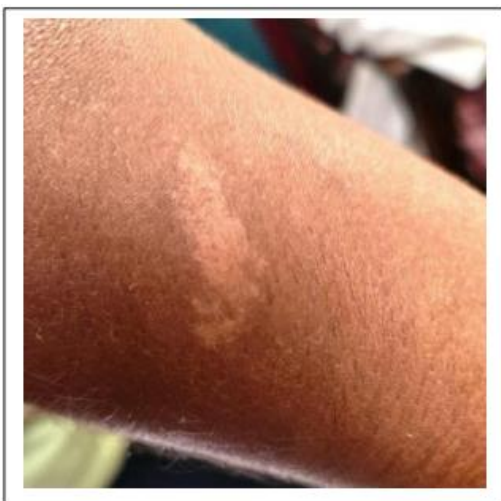(Red arrow) showing diffuse white area with ill defined margins (Black arrow) showing reticular pigment network



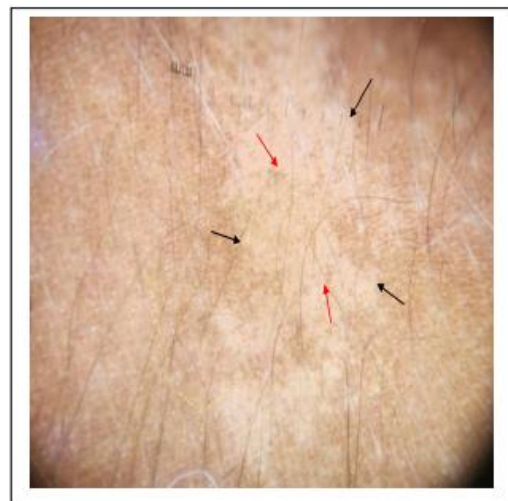
CLINICAL PICTURE OF PROGRESSIVE MACULAR



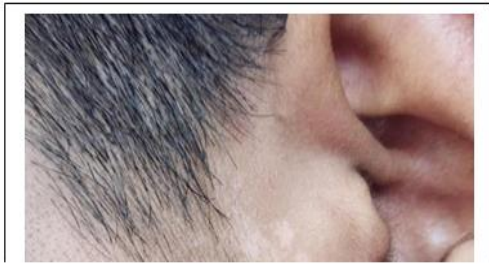Blue circle showing diffuse white area black arrow showing reticular pigment at some Places of white areas.



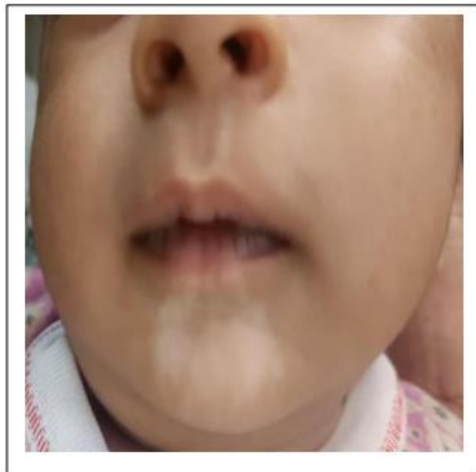
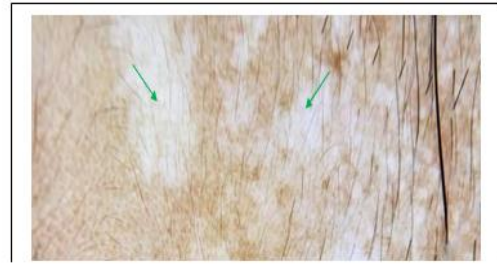
CLINICAL PICTURE OF NEVUS DEPIGMENTOSUS OVER FOREARM



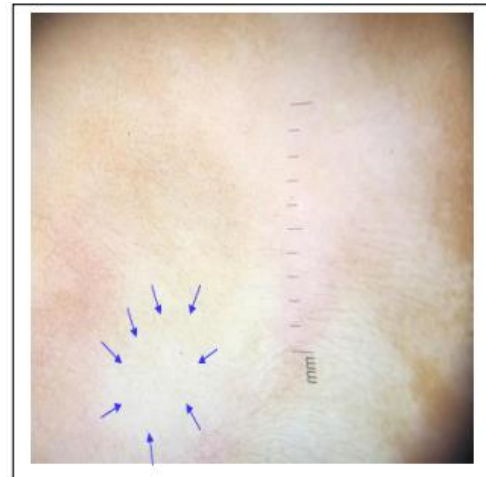Red arrow showing irregular serrated borders (green arrow) decreased pigment network.



CLINICAL PICTURE OF NEVUS DEPIGMENTOSUS



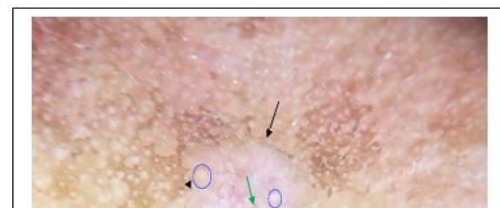
CLINICAL PICTURE OF NEVUS ANEMICUS



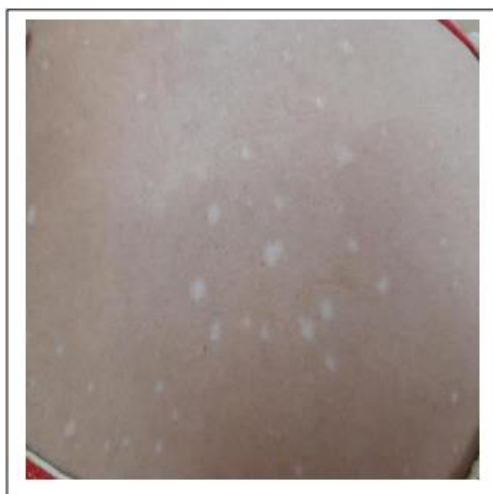(Blue arrow) showing focal area of decreased vasculature.



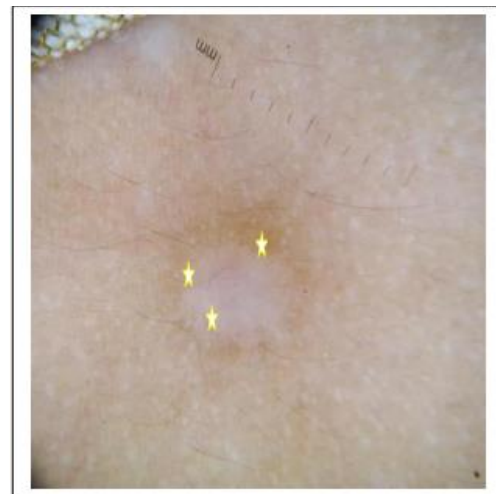CLINICAL PICTURE OF EXTRAGENITAL LICHEN SCLEROSUS ET ATROPHICUS



(Black arrow) white structure less area with well defined borders. (Green arrow) telangiectasia of different length (Blue circle) – follicular plugging of white areas.



CLINICAL PICTURE OF EXTRA GENITAL LICHEN SCLEROSUS ET ATROPHICUS OVERBACK



White structure less areas with hyperpigmented borders.(yellow star) Linear vessel like telangiectasia (black arrow)

DISCUSSION

A total of 100 cases of various hypopigmented disorders were included in the study. In our study a total of 100 patients of various hypopigmentary disorders were included ranging from 0 years to 70 years. Majority of patients were between 21-30 years age group with 23% cases, followed by 22% cases between 11-20 years. On the contrary, Swapnarani et al. reported in their study³ that most patients were in the 0-14 yr age group i.e., 108 (38.98%) while least patients were in the 30-44 year age group i.e. 28 (10.1%).³ In our study, out of 100 patients, 50 (50%) were male and 50 (50%) were females. In a study by Swapnarani et al., a total of 277 patients were included in the study out of which 174 (62.8%) patients were male and 103 (37.2%) patients were female. Male to female ratio was 1.68:1.³ Mareddy et al. conducted a study in which a total of 123 patients with hypopigmented lesions were included in the study. Out of 123 patients, 55.3% were females and 44.7% were males.⁴ Among 100 cases of hypopigmentary disorders that were included in our study, vitiligo (in evolution) was seen in 21% cases, achromic pityriasis versicolor in 19% cases, pityriasis alba in 15% cases, idiopathic guttate hypomelanosis in 16% cases, post inflammatory hypopigmentation in 11% cases, leprosy in 7% cases, progressive macular hypomelanosis in 4% cases, Nevus depigmentosus in 3% cases, Nevus anemicus in 2% cases and extra genital LSA in 2% cases. In a study by Mareddy et al. vitiligo was seen in 34 patients (27.64%) followed by tinea versicolor in 26 patients (21.1%).⁴ Similarly, pityriasis versicolor was the most common disease observed (105 cases) followed by idiopathic guttate hypomelanosis (45 cases) and vitiligo (36 cases) in a study conducted by Swapnarani et al.³

The study conducted in our department included 21 cases of vitiligo (in evolution). Among 21 cases studied, 12 cases had reduced pigment network, 9 cases had absent pigment network while 4 cases had reverse pigment network. Trichrome border was seen in 2 cases. Satellite lesions and micro koebnarization were seen a few cases. Diffuse white glow was common finding. In study by Thatte et al.,⁵ patients experiencing progressive vitiligo for less than one month, showed that the predominant dermatoscopic patterns were a diminished or absent pigment network and an inverted pigment network.⁶ They observed that perifollicular and perilesional hyperpigmentation were infrequent occurrences. In their study involving one hundred cases, Wali et al. identified distinct dermatoscopic patterns associated with various stages of disease evolution.⁷ In stable vitiligo, the most common patterns observed were reticular, perifollicular, and marginal pigmentation. Conversely, progressive vitiligo exhibited trichromic patterns such as salt and pepper, starbursts, and comet tails. A total of 21 cases of pityriasis versicolor were included in our study. On dermatoscopy, hypopigmented structure less area were seen in 19 cases with a decreased

pigment network in 12 cases. The characteristics observed on dermatoscopy were the presence of white scales within the lesions in the furrows in 7 cases along with perifollicular scaling in 13 cases. The most common pigmentary change observed on dermatoscopy among pityriasis versicolor patients in a study conducted by Swapnarani et al. was reduced pigmentation seen in all 105 cases and Scaling seen in 103 cases (98.09%).³ Mathur et al. studied a total of 178 lesions from 125 patients of pityriasis versicolor and reported nonuniform pigmentation and scaling as most common findings.⁸ Fifteen cases of pityriasis alba were included in our study. On dermatoscopy, brownish white background and decreased pigment network in most of the cases. Characteristic feature observed on dermatoscopy were the presence of focal white scales within the lesions in 13 cases. Thomas et al. studied 16 cases of clinically diagnosed pityriasis alba and reported that white structureless spots, scaling, indistinct borders and normally pigmented hairs were consistently present in dermatoscopy of all the cases.⁹ We conducted dermatoscopy of 16 cases of idiopathic guttate hypomelanosis, Homogenous white background was seen in 16 cases with a decreased pigment network in 6 cases. Amoeboid borders were seen in 7 of cases, feathery margins in 6 cases, petaloid margins in 2 cases and nebuloid margins in 1 case. Mareddy et al. reported multiple shiny white macules with well to ill-defined borders and residual pigment network. The borders were amoeboid (50%), feathery (50%), petaloid (40%), and nebuloid (10%).⁴ A total of 11 cases of post inflammatory hypopigmentation were include in our study. Homogenous white structureless area was seen in 3 cases with white glow in 2 cases while pinkish white background in 6 cases. Decreased pigment network was the most common finding. Telangiectasia was observed in 6 cases while dotted vessels were seen in 3 cases. Mareddy et al. studied dermatoscopy of post inflammatory hypopigmentation and reported decreased pigment network in most of the cases along with white glow, perifollicular pigmentation, grey-blue and brown globules on pinkish-white background and telangiectasia.⁴ A total of 7 cases of hypopigmented patches of leprosy were studied. Among these, orange yellow background was seen in 3 cases while brownish white background was seen in 4 cases. Focal white areas and diffuse white scales with distorted pigment network were other common findings. Reduced eccrine and follicular openings were seen in 6 cases. Similarly, Mohta A et al. conducted a study on dermatoscopic aspects of leprosy. They reported orangish yellow and white structureless areas, steadily throughout the spectrum, depicting dermal granuloma. Other findings were telangiectatic vessels and loss of hair follicles with relative sparing of vellus hair, absence of white dots (sweat gland openings) and loss of pigment network.¹⁰ Dermatoscopy of progressive macular hypomelanosis showed diffuse

white areas with reduced pigment network and ill defined margins were seen in all 4 cases with minimal scaling was observed in 2 cases. All three cases of nevus depigmentosus showed uniform white background, decreased pigment network and Irregular serrated borders. Similarly, Ankad et al. reported whitish structureless areas covering the entire lesion with pseudopods at periphery and subtle pigment network in dermatoscopy of nevus depigmentosus.¹¹ Mareddy et al. reported well-defined hypopigmented macules with feathery margins with decreased pigment network in six cases of nevus depigmentosus.⁴ We studied two cases of nevus anemicus. Both the cases showed normal pigmentary network, pale brownish white background and focal areas of decreased vasculature. Thakur et al. reported paucity of blood vessels in the lesional skin with diffuse erythema and linear telangiectatic vessels indicating compensatory flare in the surrounding skin on dermatoscopy of nevus anemicus.¹² We observed two cases of extra genital lichen sclerosus et atrophicus. Both the cases showed white structureless areas with well defined margins. Telangiectasia was seen in both the cases while follicular plugging was seen in one case. Mareddy et al. studied 6 cases which showed white structureless areas, pinkish white background, follicular plugs and telangiectasias on dermatoscopy in all the lesions.⁴

CONCLUSION

Based on this study, specific dermatoscopic characteristics were identified for certain hypopigmented macular disorders. However, some dermatoscopic findings in these conditions were found to be non-specific. Therefore, dermatoscopy is a non-invasive procedure that may confirm the diagnosis of hypopigmented skin lesions alongside history and clinical examination, thus eliminating the necessity for biopsy. It also aids in evaluating the activity and stability of conditions such as vitiligo.

REFERENCES

1. Poon S, Beach RA. Localised hypopigmentation: clarification of a diagnostic conundrum. *Br J Gen Pract.* 2018;68:444-445.
2. Madireddy S, Crane JS. Hypopigmented Macules. [Updated 2023 Jun 28]. In: StatPearls [Internet]. Treasure Island (FL): StatPearls Publishing; 2024 Jan.
3. Swapnarani B, Saswat PK, Sandhyarani P, Sandeep L, Jayashree M, Manoj RK et al. Study of Clinical and Dermoscopic Features of Hypopigmented Lesions: An Observational Study *Int J of Phar and Clin Res.* 2024; 16(1); 564-575
4. Mareddy M, P. M, Kareddy S. Clinical and dermoscopic assessment of patients with hypopigmented skin lesions - a cross-sectional study. *Turkderm-Turk Arch Dermatol Venereol* 2023;57:138-44
5. Shah A, Koticha A, Ubale M, Wanjare S, Mehta P, Khopkar U. Identification and speciation of Malassezia in patients clinically suspected of having pityriasis versicolor. *Indian J Dermatol.* 2013;58(3):239.
6. Thatte SS, Khopkar US. The utility of dermatoscopy in the diagnosis of evolving lesions of vitiligo. *Indian J Dermatol Venereol Leprol.* 2014;80(6):505-508.
7. Wali V, Deepali M, Hogade A. A panoramic study of dermoscopic patterns in vitiligo. *Medpulse - int med j.* 2016;3:436-9. 33.
8. Mathur M, Acharya P, Karki A, Kc N, Shah J. Dermoscopic pattern of pityriasis versicolor. *Clin Cosmet Invest Dermatol.* 2019 Apr 30;12:303-309.
9. Thomas IN, James JJ, Bala A, Mohan S, Dogiparthi S, Shanmugam NP Sr. Usage of Dermoscopy as an Effective Diagnostic Tool in Pityriasis Alba: A Prospective Observational Study Among Children in a Suburban Hospital in South India. *Cureus.* 2023 Jun 11;15(6):e40271.
10. Mohta A, Jain SK, Agrawal A, Kushwaha RK, Sharma P, Sethia K, Jain M. Dermoscopy in Leprosy: A Clinical and Histopathological Correlation Study. *Dermatol Pract Concept.* 2021 Apr 12;11(2):e2021032.
11. Ankad, Balachandra S.; Shah, Swapnil. Dermoscopy of Nevus Depigmentosus. *Pigment International* 2017; 4(2):p 121-123.
12. Thakur V, Dev A, Vinay K. Dermoscopy of Nevus Anemicus. *Indian Dermatol Online J.* 2021;13(6):822-823.