

**ORIGINAL RESEARCH**

# Assessment of variations of nutrient foramen in the clavicle

<sup>1</sup>Dr. Babita Priti, <sup>2</sup>Dr. Amresh Kumar, <sup>3</sup>Dr. Manish Kumar

<sup>1</sup>Tutor, Department of Anatomy, GMCH Purnea, Bihar, India

<sup>2</sup>Medical Officer, Department of Anatomy, Village & Post –Sori District –Aurangabad P. S – Mali Bihar, India

<sup>3</sup>Tutor, Department of Anatomy, JNKTMCH Madhepura, Bihar, India

## Corresponding Author

Dr. Babita Priti

Tutor, Department of Anatomy, GMCH Purnea, Bihar, India

Received Date: 22 May, 2024

Acceptance Date: 20 June, 2024

## ABSTRACT

**Background:** The clavicle, a modified long bone situated nearly horizontally at the base of the neck, is well known. The present study was conducted to assess variations of nutrient foramen in the clavicle. **Materials & Methods:** 58 dried human clavicle bones of both genders were selected. Parameters such as number of nutrient foramina, position of foramen, etc. were recorded. **Results:** On medial 1/3<sup>rd</sup>, there were 5 foramina in left and 3 in right clavicle, on middle 1/3<sup>rd</sup>, 20 in left and 18 in right and on lateral 1/3<sup>rd</sup>, 5 in left and 8 in right clavicle. The difference was non-significant ( $P > 0.05$ ). There was 1 foramen in 19 left and 18 right clavicles, 2 in 7 left and 6 right and 3 in 3 left and 5 right clavicles. The difference was non-significant ( $P > 0.05$ ). The position of foramen was superior in 2 left and 1 right, inferior in 6 left and 8 right and posterior in 21 left and 20 right clavicles. The difference was non-significant ( $P > 0.05$ ). **Conclusion:** To protect the artery supply during surgical procedures such as internal fixation and vascularized bone graft, it is helpful to examine the quantity, orientation, location, and direction of the clavicles' nutritional foramina.

**Keywords:** clavicle, foramen, Bone

This is an open access journal, and articles are distributed under the terms of the Creative Commons Attribution- Non Commercial-Share Alike 4.0 License, which allows others to remix, tweak, and build upon the work non-commercially, as long as appropriate credit is given and the new creations are licensed under the identical terms.

## INTRODUCTION

The clavicle, a modified long bone situated nearly horizontally at the base of the neck, is well known. It is subcutaneous all the way around. The clavicle transfers the upper limb's weight to the axial skeleton. The clavicle is comprised of a cylindrical shaft and two ends, medial and lateral.<sup>1</sup> There are two sections of the shaft: the medial and lateral sections. The lateral third of the shaft flattens downward from above. It has two surfaces, superior and inferior, and two borders, anterior and posterior. It has a convex posterior border and a concave anterior border. The subcutaneous layer is the superior surface. The inferior surface is higher. It is referred to as the trapezoid ridge and the conoid tubercle.<sup>2</sup>

When it comes to pathological circumstances like acute hemogenic osteomyelitis, developmental anomalies, and fracture repair, the nutritional artery serves as the primary blood supply to the bones.<sup>3</sup> The suprascapular artery gives rise to the nutrient artery, which is located at the clavicle's lateral to laterally directed subclavian groove. The nutrient foramen, which allows the artery to pass through the clavicle, is located at the intersection of the middle and lateral thirds of the clavicle. The position and quantity of

nutritional foramina in long bones continue to vary. At the lateral end of the subclavian groove that runs in a lateral direction is a nutrient foramen of the clavicle.<sup>4</sup> However, a study revealed that the nutritional artery is absent and that the clavicle is only nourished by periosteal arteries. Conversely, the clavicle's nutritional foramina are therapeutically significant. These aid in the healing of clavicular fractures, which can result in neurovascular complications such as brachial plexus damage and supraclavicular nerve entrapment syndrome.<sup>5</sup> The present study was conducted to assess variations of nutrient foramen in the clavicle.

## MATERIALS & METHODS

The present study was conducted on 58 dried human clavicle bones of both genders. All were informed regarding the study and their written consent was obtained.

Data such as name, age, etc. was recorded. Parameters such as number of nutrient foramina, position of foramen, etc. were recorded. Data thus obtained were subjected to statistical analysis.  $P$  value  $< 0.05$  was considered significant.

## RESULTS

**Table I Distribution according to nutrient foramen of clavicle**

Parameters	Left (29)	Right (29)	P value
Medial 1/3rd	5	3	0.94
Middle 1/3rd	20	18	
Lateral 1/3rd	5	8	

Table I shows that on medial 1/3<sup>rd</sup>, there were 5 foramina in left and 3 in right clavicle, on middle 1/3<sup>rd</sup>, 20 in left and 18 in right and on lateral 1/3<sup>rd</sup>, 5 in left and 8 in right clavicle. The difference was non-significant ( $P > 0.05$ ).

**Table II Assessment of number of nutrient foramina in clavicle**

Number	Left (29)	Right (29)	P value
1	19	18	0.52
2	7	6	
3	3	5	

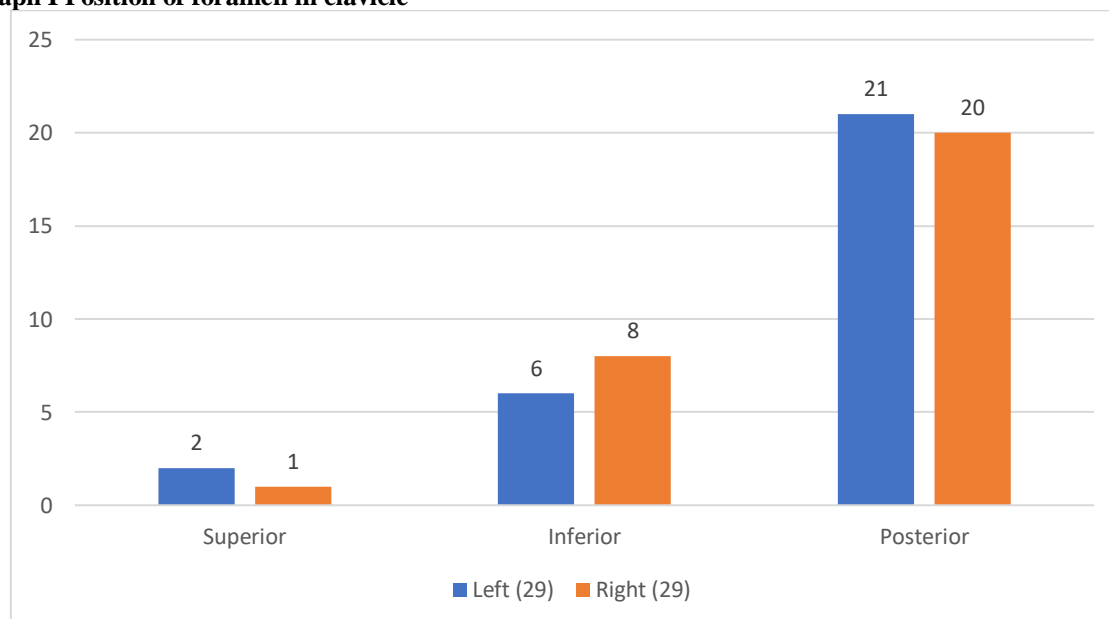
Table II shows that there was 1 foramen in 19 left and 18 right clavicles, 2 in 7 left and 6 right and 3 in 3 left and 5 right clavicles. The difference was non-significant ( $P > 0.05$ ).

**Table III Position of foramen in clavicle**

Surface	Left (29)	Right (29)	P value
Superior	2	1	0.28
Inferior	6	8	
Posterior	21	20	

Table III, graph I shows that position of foramen was superior in 2 left and 1 right, inferior in 6 left and 8 right and posterior in 21 left and 20 right clavicles. The difference was non-significant ( $P > 0.05$ ).

**Graph I Position of foramen in clavicle**



## DISCUSSION

To maintain the circulation of the impacted bone structure, knowledge regarding the anatomical description of these foramina is essential.<sup>6,7</sup> It is especially pertinent to orthopedic surgeons who perform surgical procedures where maintaining arterial supply patency is essential for supporting fracture healing. An essential component of free vascular bone grafting is the blood supply for nutrients.<sup>8,9</sup> It needs to be preserved to support bone mending, provide a healthy blood supply for the

survival of osteoblast and osteocyte cells, and aid in the recipient's graft healing. For the afflicted bony structure to continue to circulate, anatomical information about the nutritional foramen of the clavicle is crucial.<sup>10,11</sup> The present study was conducted to assess variations of nutrient foramen in the clavicle.

We found that on medial 1/3<sup>rd</sup>, there were 5 foramina in left and 3 in right clavicle, on middle 1/3<sup>rd</sup>, 20 in left and 18 in right and on lateral 1/3<sup>rd</sup>, 5 in left and 8 in right clavicle. Motwali et al<sup>12</sup> included total 60 dried

human clavicle bones. This study revealed the different number, position & direction of nutrient foramina of clavicle. It was found that in 65 % bone one foramen was present, while two nutrient foramen was present in 26.7% clavicle bones & three nutrient foramen in 8.4% clavicle bones.

We observed that there was 1 foramen in 19 left and 18 right clavicles, 2 in 7 left and 6 right and 3 in 3 left and 5 right clavicles. Singh et al<sup>13</sup> performed morphometric analysis of the variations in the number, position, and direction of nutrient foramen in the clavicle. They examined 60 dry humeri (30 right and 30 left) of unknown genders. (3.33%) of the humerus specimens lacked nutrient foramina. A solitary nutrient foramen was detected in 28 (46.67%) of the right humerus, 27 (45%) of the left humerus, and 55 (91.67%) of the whole humerus. Two nutrient foramina were detected in 1 (1.33%) of the right humerus, 1 (1.33%) of the left humerus, and 2 (3.33%) of the whole humerus. Only one (1.67%) of the left humerus specimens showed the presence of three nutrient foramen. Among the total of 60 nutritional foramina, 88.33% were located on the anteromedial surface, 86.67% on the right side, and 90% on the left side. Out of all the nutritional foramen, 10% were located on the anterolateral surface, with an equal distribution of 10% on the right side and 10% on the left side. The posterior surface included 1.67% of the nutritional foramen, with 3.33% located specifically on the right side. Out of a total of 60 nutrient foramen, the maximum number was observed in the middle one-third of the shaft (86.67%), followed by the distal third (13.33%). No nutrient foramen was found on the proximal one-third of the shaft.

We found that position of foramen was superior in 2 left and 1 right, inferior in 6 left and 8 right and posterior in 21 left and 20 right clavicles. Kumar et al<sup>14</sup> found that nutrient foramina were present in 50 clavicles (Right) and 44 clavicles (left). Out of which single foramina in 41 clavicles (Right) and 36 clavicles (Left), double foramina in 9 clavicles (Right) and 6 clavicles (left) and three foramina in 2 clavicles (Left). Absence of nutrient foramina were found in 2 clavicles (Right) and 8 clavicles (Left). Maximum number was present in the medial 2/3 and on the posterior surface of 46 bones (Right) and 34 Bones (Left). All foramina were directed towards the acromial end.

The shortcoming of the study is small sample size.

## CONCLUSION

Authors found that to protect the artery supply during surgical procedures such as internal fixation and vascularized bone graft, it is helpful to examine the quantity, orientation, location, and direction of the clavicles' nutritional foramina.

## REFERENCES

1. Freyschmidt J, Sternberg A, Brossmann J, Wiens J (2003) Borderlands of normal and early pathological findings in skeletal radiography, 5th edn. Thieme, New York, p 305- 318.
2. Lewis O.J. The blood supply of developing long bones with special reference to the metaphysic. *J Bone JtSurg*1956;38:928-33.
3. Johnson R. W. A Physiological study of the Blood Supply of the Diaphysis. *J Bone JtSurg*1927;9:15.
4. Watson-Jones, Sir R. *Fractures and Joint Injuries*, 4th Edition. Edinburgh and London: E. & S. Livingstone Ltd., 1955.
5. Joshi H, Doshi B, Malukar O. A study of the nutrient foramina of the humeral diaphysis. *NJIRM* 2011;2:14-17.
6. Ojaswini Malukar, Hemang Joshi, Diaphysial Nutrient Foramina in long Bones sand Miniature Long Bones. *NJIRM* 2011;2(2):23-6.
7. Rahul Rai, Shailaza Shrestha, B Kavitha (2014) Morphological and topographical anatomy of nutrient foramen in clavicles and their clinical importance. *IOSR J Dent Med Sci* 2014;13(1):37-40.
8. Murlimanju BV, Prabhu LV, Pai MM, Yadav A, Dhananjaya KV, Prashanth KU. Neurovascular foramina of the human clavicle and their clinical significance. *SurgRadiol Anat* 2011;33(8):679.
9. Mansur DI, Manadhar P, Haque MK, Mehta DK, Duwal S, Timalina B. A study on variations of nutrient foramen of humerus with its clinical implications. *Kathmandu Univ Med J.* 2016;53:78-83.
10. Khan AS, Shah Z, Qaiser I. Anatomical variations in diaphyseal nutrient foramina of humerus in cadavers from Khyber Pakhtunkhwa, Pakistan. *Khyber Med Univ J.* 2014;6:18-21.
11. Yaseen S, Nitya W. Morphological and topographical study of nutrient foramina in adult humeri. *Int J Innov Res Dev.* 2014;3:7-10.
12. Veena Motwani, Md. Tabrej Alam, Mohd Arshad, Deepanshu Shukla, Sobha Bhatnagar. Morphometric Study in the Variations of Number, Position and Direction of Nutrient Foramen in the Clavicle. *International Journal of Health and Clinical Research,* 2021;4(23):224-226.
13. Singh DV, Sirohi DK. Morphometric analysis of the variations in the number, position, and direction of nutrient foramen in the clavicle. *Int J Acad Med Pharm.* 2023;5(4):2109-13.
14. Kumar D, Raichandani L, Kataria SK, Singh J. Variation in number and position of nutrient foramen of clavicle—A morphological study in western Rajasthan. *IP Indian J Anat Surg Head Neck Brain.* 2019;5(3):67-71.