

**ORIGINAL RESEARCH**

# Assessment of variation of renal vasculature

<sup>1</sup>Dr. Babita Priti, <sup>2</sup>Dr. Manish Kumar, <sup>3</sup>Dr. Amresh Kumar

<sup>1</sup>Tutor, Department of Anatomy, GMCH Purnea, Bihar, India

<sup>2</sup>Tutor, Department of Anatomy, JNKTMCH Madhepura, Bihar, India

<sup>3</sup>Medical Officer, Department of Anatomy, Village & Post –Sori District –Aurangabad P. S - Mali Bihar, India

**Corresponding Author**

Dr. Babita Priti

Tutor, Department of Anatomy, GMCH Purnea, Bihar, India

Received Date: 25 May, 2024

Acceptance Date: 23 June, 2024

**ABSTRACT**

**Background:**The renal vasculature refers to the network of blood vessels that supply the kidneys. The present study was conducted to evaluate variation of renal vasculature.

**Materials & Methods:**44 formalin fixed human cadavers of both genders were selected. The renal arteries were observed according to their number (sum of renal arteries originating from the aorta) and early segmental and extra hilar branches of the main renal artery on each kidney.

**Results:** In right kidney, single renal artery was seen in 22 and multiple in 22 cases and in left kidney, single renal artery was seen in 24 and multiple in 20 cases. The difference was non- significant ( $P > 0.05$ ). Multiple renal arteries in right kidney and left kidney was double hilar arteries in 8 and 7, three hilar arteries in 5 and 4, hilar and superior polar artery in 4 and 5 and hilar and inferior polar artery in 5 in right and 6 in left kidney respectively. The difference was non- significant ( $P > 0.05$ ). Extra hilar superior polar artery in right kidney was 8 and in left kidney was 7 and extra hilar inferior polar artery in right kidney was 5 and in left kidney was 1 in number. The difference was non- significant ( $P > 0.05$ ).

**Conclusion:** The vascularization of the kidney varies anatomically in a wide range of ways. The most frequent occurrence is the presence of many renal arteries. Knowledge of these differences is essential for urological procedures, renal transplant surgery, abdominal aortic aneurysm repair, and angiographic procedures.

**Keywords:** Abdominal aorta, Renal vasculature, Kidney

This is an open access journal, and articles are distributed under the terms of the Creative Commons Attribution- Non Commercial-Share Alike 4.0 License, which allows others to remix, tweak, and build upon the work non-commercially, as long as appropriate credit is given and the new creations are licensed under the identical terms.

**INTRODUCTION**

The renal vasculature refers to the network of blood vessels that supply the kidneys. The kidneys play a crucial role in filtering blood, removing waste products, and regulating various body functions, and the renal vasculature is essential for their proper function.<sup>1</sup>Renal artery and vein variations are frequently observed in kidneys.<sup>2</sup> A thorough understanding of the variances in the kidney's anatomical pattern of vasculature is necessary for the current generation of advanced renal procedures, including transplants. A renal artery is a branch of the abdominal aorta that is often bilateral or paired.<sup>3</sup> The kidney's hilum is where the vein usually empties into the inferior vena cava. Additional or accessory renal vessels can enter the kidney in a variety of ways, including the hilum, the kidney's surface, or its upper or lower pole as polar arteries. These vessels can then be used as a useful platform for renal conservative surgeries, urological or radiological procedures, and the treatment of hydronephrosis.<sup>4</sup>

Narrowing of the renal arteries, which can lead to hypertension and reduced kidney function. Atherosclerosis can affect the renal arteries, leading to impaired blood flow. In renal vein thrombosis blood clots in the renal vein, which can cause kidney damage. High blood pressure can damage the renal vasculature over time. Diabetes can lead to changes in the renal vasculature, causing kidney damage.<sup>5</sup>The present study was conducted to evaluate variation of renal vasculature.

**MATERIALS & METHODS**

The present study was conducted on 44 formalin fixed human cadavers of both genders.

Data such as name, age, gender etc. was recorded. During a standard dissection, the abdomen was opened, the anterior abdominal wall and its muscles were reflected, the peritoneum was then removed, and lastly the kidneys were taken. Veins and renal arteries were located. The renal vasculature's variations were documented and captured on camera. The renal

arteries were observed according to their number (sum of renal arteries originating from the aorta) and early segmental and extra hilar branches of the main renal artery on each kidney. The relationship between the

renal vein, renal artery, and pelvis was also seen and documented. Data thus obtained were subjected to statistical analysis. P value < 0.05 was considered significant.

## RESULTS

**Table I Distribution of renal arteries**

Parameters	Right kidney (44)	Left kidney (44)	P value
Single renal artery	22	24	0.90
Multiple renal arteries	22	20	

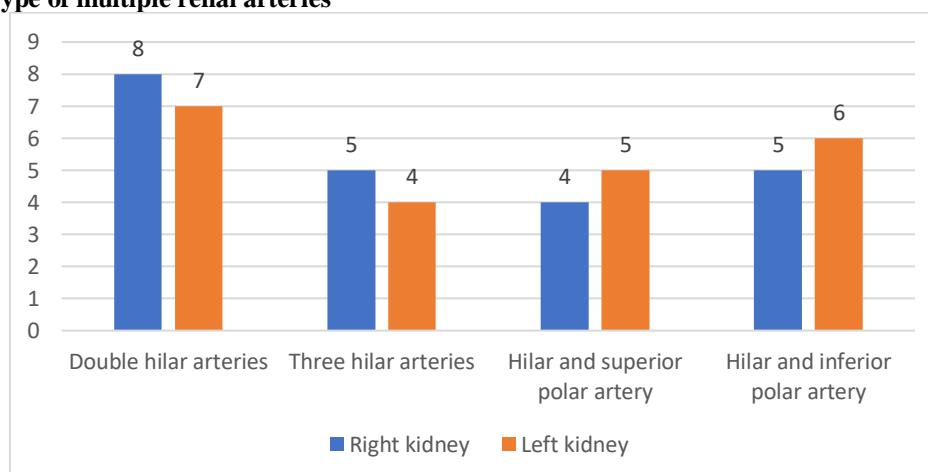
Table: I shows that in right kidney, single renal artery was seen in 22 and multiple in 22 cases and in left kidney, single renal artery was seen in 24 and multiple in 20 cases. The difference was non- significant (P> 0.05).

**Table: II Type of multiple renal arteries**

Multiple renal arteries	Right kidney	Left kidney	P value
Double hilar arteries	8	7	0.75
Three hilar arteries	5	4	
Hilar and superior polar artery	4	5	
Hilar and inferior polar artery	5	6	

Table; II shows that multiple renal arteries in right kidney and left kidney was double hilar arteries in 8 and 7, three hilar arteries in 5 and 4, hilar and superior polar artery in 4 and 5 and hilar and inferior polar artery in 5 in right and 6 in left kidney respectively. The difference was non- significant (P> 0.05).

**Graph: I Type of multiple renal arteries**



**Table: III Distribution of extra-hilar branch of renal artery**

Arterial features	Right kidney	Left kidney	P value
Extra-hilar superior polar	8	7	0.52
Extra-hilar inferior polar	5	1	

Table III shows that extra hilar superior polar artery in right kidney was 8 and in left kidney was 7 and extra hilar inferior polar artery in right kidney was 5 and in left kidney was 1 in number. The difference was non-significant (P> 0.05).

## DISCUSSION

Renal artery variations have been referred to as aberrant, supernumerary, supplemental, and auxiliary, among other designations.<sup>6</sup> Standardizing the morphology and terminology of these vessels is therefore imperative. These arteries are segmental channels for the kidneys and do not have anastomoses between them.<sup>7,8</sup> Therefore, they should be referred to

as multiples, and their names should correspond to the territory they supply, namely ashilar, superior polar, and inferior polar.<sup>9,10</sup> The present study was conducted to evaluate variation of renal vasculature. We observed that in right kidney, single renal artery was seen in 22 and multiple in 22 cases and in left kidney, single renal artery was seen in 24 and multiple in 20 cases. Budhiraja et al<sup>11</sup> determined prevalence of multiple renal arteries in Indian population. The formalin fixed forty- two cadavers constituted the material for study. They observed multiple renal arteries originating from abdominal aorta in 54.7% cases which includes Double hilar arteries(22.6%), Three hilar arteries(11.8%), hilar and superior polar

(13.1%), hilar and inferior polar artery (7.1%). We observed that multiple renal arteries in right kidney and left kidney was double hilar arteries in 8 and 7, three hilar arteries in 5 and 4, hilar and superior polar artery in 4 and 5 and hilar and inferior polar artery in 5 in right and 6 in left kidney respectively. Harsh et al<sup>12</sup> in thirty-two formalin fixed human cadavers, kidneys were exposed after abdominal dissection, and variations in vasculature were noted. Results showed additional or accessory renal arteries ii. pre hilar branching of arteries.iii.polar arteries.iv. additional or accessory renal vein.

We observed that extra hilar superior polar artery in right kidney was 8 and in left kidney was 7 and extra hilar inferior polar artery in right kidney was 5 and in left kidney was 1 in number. Aremu et al<sup>13</sup> reported the various anatomical configurations of the renal artery identified in living kidney donors. The computerized tomography angiograms of 100 consecutive living kidney donors were prospectively reviewed. Anatomical variations of the renal arteries including accessory arteries and early divisions were noted. Duration of surgery and ischemic time were recorded intra-operatively. There were variations in renal artery configuration in 50 (50%) cases, 32% were accessory renal arteries while 18% were early branches of the renal artery. The classical bilateral solitary renal arteries were found in 50 (50%) of potential donors. There was statistically significant longer operating and ischemic time in donors with multiple renal arteries as compared with solitary arteries ( $p < 0.05$ ).

## CONCLUSION

Authors found that the vascularization of the kidney varies anatomically in a wide range of ways. The most frequent occurrence is the presence of many renal arteries. Knowledge of these differences is essential for urological procedures, renal transplant surgery, abdominal aortic aneurysm repair, and angiographic procedures.

## REFERENCES

1. Saldarriaga AF, Perez LE, Ballesteros A direct anatomical study of additional renal arteries in a Colombian Mestizo population. *Folia Morphol.* 2008;67:129–34.
2. Felix WN. *Manual of human embryology*, Keibel and Mall. (2nd ed) 1912:833.
3. Budhiraja Virendra, Asthana AK. Renal artery variations: embryological basis and surgical correlation. *Romanian Journal of Morphology and Embryology.* 2010;51(3):533–36.
4. Bordei P, Saote E, Iliescu D. Double renal arteries originating from the aorta. *Surg. Radiol. Anat.* 2004;26(6):474–79.
5. Gupta Anupma, Singal Rikki. Congenital variations of renal veins: Embryological background and clinical implications. *Journal of Clinical and Diagnostic Research.* 2011;6:1140–43.
6. Testut L, Laterjet A. *tratado de anatomia Humana.* 8th ed. Barcelona: salvat; 1947. p. 4.

7. Thatipelli MR, Sabater EA, Bjarnason H, McKusick MA, Misra S. CT angiography of renal artery anatomy for evaluating embolic protection devices. *J Vasc Interv Radiol.* 2007;18(7):842–846.
8. Awojobi OA, Ogunbiyi OA, Nkposong EO. Unusual relationship of multiple renal arteries. *Urology.* 1983;21(2):205–206.
9. Cicekcibasi AE, Ziylan T, Salbacak A, Seker M, Buyukmumcu M, Tuncer I. An investigation of the origin, location and variations of the renal arteries in human fetuses and their clinical relevance. *Annals of anatomy.* 2005;187:421–427.
10. Shakeri AB, Tubbs RS, Shoja MM, Pezeshk P, Farahani RM, Khaki AA, et al. Bipolar supernumerary renal artery. *SurgRadiol Anat.* 2007;29(1):89–92.
11. Budhiraja V, Rastogi R, Jain V, Bankwar V. Anatomical variations of renal artery and its clinical correlations: A cadaveric study from central India. *Journal of morphological sciences.* 2017 Jan 16;30(4):0-.
12. Harsh, Shishirkumar C Naik, Prabhjot Kaur, Shaswati Athaiya, Harmeet Kaur, Pooja Garg, Maitree Sharma. Variation of Renal Vasculature and Its Clinical Correlation. *International Journal of Health and Clinical Research,* 2021;4(15):126-128.
13. Aremu A, Igbokwe M, Olatise O, Lawal A, Maduadi K. Anatomical variations of the renal artery: a computerized tomographic angiogram study in living kidney donors at a Nigerian Kidney Transplant Center. *African Health Sciences.* 2021 Sep 27;21(3):1155-62.