International Journal of Life Sciences, Biotechnology and Pharma Research Vol. 13, No. 6, June 2024 Online ISSN: 2250-3137
Print ISSN: 2977-0122

DOI: 10.69605/ijlbpr_13.6.2024.57

ORIGINAL RESEARCH

Study of surgical management of distal 1/3rd extra articular tibia fracture with locking compression plate a prospective study

[1]Dr. Srujith Kommera, [2]Dr. Atif Baig, [3]Dr. Pradeep Kumar Reddy, [4]Dr. Farhaan Mohammed Nasar

[1,2]Associate Professor, [4]Postgraduate Student, Department of Orthopaedics, Shadan Medical College and Hospital, India
[3]Assistant Professor, Department of Orthopaedics, Ayaan Medical College and Hospital, India

Corresponding Author
Dr. Srujith Kommera
Associate Professor, Department of Orthopaedics, Shadan Medical College and Hospital, India
Email: kommerasrujith@gmail.com

Received date: 16 May, 2024 Acceptance date: 10 June, 2024

ABSTRACT

Objective: To study the advantages of locking compression plate in management of distal tibia extra articular fracture and to study its complications. **Methods:** This prospective study was carried out in the Department of Orthopaedics in Shadan Institute of Medical Sciences, Teaching Hospital and Research Centre, Hyderabad, Telangana November 2022 to November 2023. Patient selection was based on Inclusion and Exclusion criteria. 25 Patients with Distal 1/3rd Extra Articular Tibia Fracture were treated with Locking Compression Plating. The patient was placed in supine position with support on greater trochanter to maintain neutral position. Fracture is primarily reduced by manual traction and pointed reduction forceps. Approach used is Direct Anterior and Anteromedial and Anterolateral. Plate is temporarily is fixed by k-wires followed by screw fixation after confirming fracture reduction using image intensifier. Post-Surgery physiotherapy was started as early as possible. Functional outcome was evaluated using Oleaur and Mollander scoring system. **Results:** All 25 patients were available for follow-up every 6weeks. Results were analyzed both clinically and radiologically. All fractures united with an average of 16-18weeks. There were 4 cases of delayed union with 21-23 weeks of radiological callus formation and 2 Patient developed superficial wound infection which resolved subsequently with use of antibiotics. Overall outcome of this study was fair and excellent. **Conclusion:** This study has yielded excellent results and shows that Locking Compression Plating (LCP) is an excellent technique for management of Extra Articular Distal 1/3rd Tibia Fracture as it promotes early fracture union

Keywords: Management/Fixation of Distal 1/3rd Extra Articular Tibia Fracture, Locking Compression Plate (LCP), Tibia, Single Column Plating, Distal Tibia, Extra Articular.

This is an open access journal, and articles are distributed under the terms of the Creative Commons Attribution- Non Commercial-Share Alike 4.0 License, which allows others to remix, tweak, and build upon the work non-commercially, as long as appropriate credit is given and the new creations are licensed under the identical terms.

INTRODUCTION

Management of distal tibial fractures can be challenging because of scarcity of soft tissue, their subcutaneous nature and poor vascularity. Management of which is at times challenging especially when soft tissues around fractures are compromised. Classic technique of ORIF with Plating increased chance of infection (range, 8.3%–23%)[1,2] and nonunion &delayed union (range, 8.3%–35%)[3,2,1,4]. Minimal invasive plating decrease chance of soft tissue injury, damage to bone and preserve fracture hematoma[4] and preserving the extrosseous blood supply[5].

Locking Compression Plate has biochemical properties of both internal and external fixator. LCP have superior holding power because of fixed angular stability[6]. In this review, the rationale for the use of LCPs for distal tibial fracture fixations are presented. Conservative management like Cast application leads to prolonged immobilization[7]. Intra-medullary nailing and plate fixation represent two approaches to internal fixation of extra-articular fractures of the distal tibia. Although both techniques have success in maintaining reduction and promoting stable union with advantages and disadvantages that require careful consideration during surgical planning[8].

©2024Int. J. LifeSci.Biotechnol.Pharma.Res.

DOI: 10.69605/ijlbpr_13.6.2024.57

LCPs gives higher degree of stability in comparison with conventional plate. The concept of MIPO helps in preserving blood supply around fractured ends and minimizing soft tissues related complications and by using indirect fracture reduction techniques.

The fundamental goal of treatment of distal tibial fractures is the restoration of a normal or a near normal alignment and articular congruity which can be achieved with locking compression plate. A recent trend in internal fixation has been a move towards locking screws implants which can rigidly stabilize cancellous fragmented bone that is normally not amenable to screw fixation.

The purpose of this study is to gain experience and to evaluate outcome following use of locking compression plate for lower third fractures of tibia and to study the advantages and complications of locking compression plate and duration of union in above mentioned fractures.

Patients selected of this operation were of different ages and genders, admitted and treated in Shadan Institute of Medical Sciences, Teaching Hospital and Research Centre, Hyderabad, during November 2021 to November 2023. Classification criteria used was AO Classification.

The anatomical position of the tibia, which makes it so vulnerable to injury particularly by direct impact also makes it scarier to approach surgically[10].

The mechanism of injury may be direct (falls, sport injuries, motor vehicle accidents or assaults) or Axial loading injuries.

CLASSIFICATION

Two classifications are important because they are commonly used and are part of the literature. Ruedi and Allgower's [11] classification was the first in common use.

1. Non displaced large fracture of the joint
2. Displaced but minimally comminuted fracture
3. Highly comminuted and displaced fracture.

The Ruedi and Allgower system has largely been supplemented by the AO/OTA classification system, and this is now universally used for fractures of the distal tibia.

In this system, distal tibial fractures are divided into the following categories:

Type A- non articular fractures;

Type B- partial articular fractures

Type C- total articular fractures.

Each category is divided into three groups based on the amount of comminution. These groups are then further divided into three subgroups by other characteristics of the fracture such as the direction, description or location of a fracture line, the presence or absence of asymmetric metaphyseal impaction, and the location and amount of comminution[12].

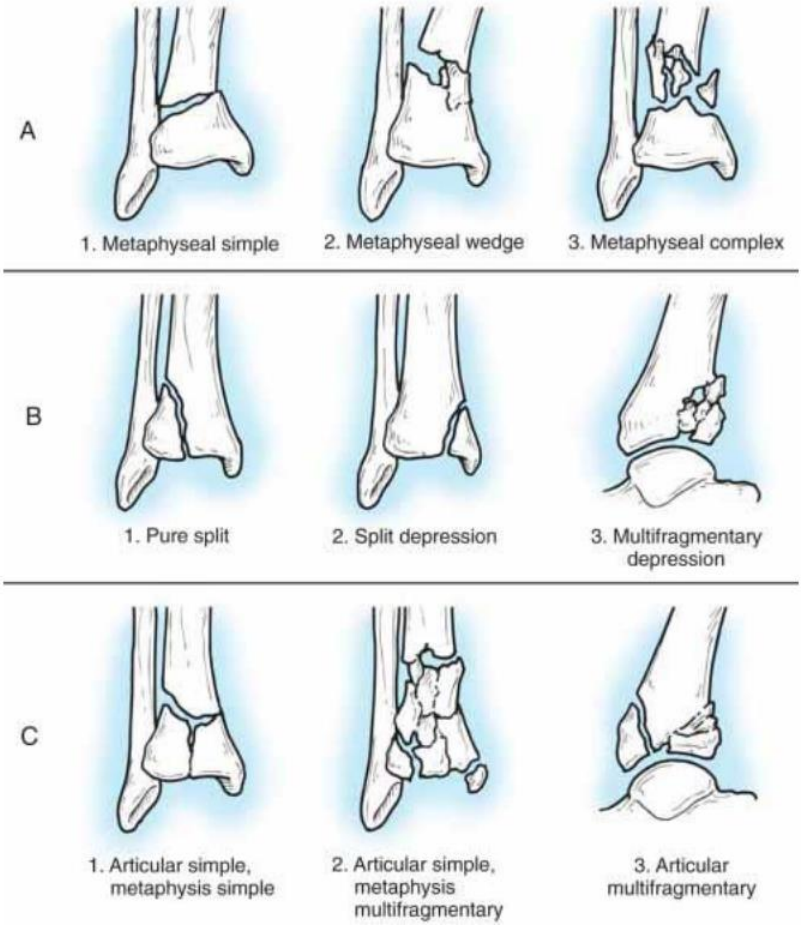

Fig 1 AO classification

©2024Int. J. LifeSci.Biotechnol.Pharma.Res.

DOI: 10.69605/ijlbpr_13.6.2024.57

Soft Tissue Injury Classification
Tsherene H and Oestern HJ[13]

	Description
0	Little or no soft tissue injury
1	Superficial abrasion with local contusional damage to skin or muscle
2	Deep contaminated abrasion with local contusional damage to skin and muscle
3	Extensive contusion or crushing of skin or destruction of muscle.

Table 1

Open Injury Classification Gustilo Anderson Classification[14]

Grade	Description
I	Open fracture, clean wound < 1cm in length
II	Open fracture, wound > 1cm but < 10cm in length without extensive soft tissue damage, flaps, avulsions
III	Open fracture with extensive soft tissue laceration (>10cm), damage or loss or an open segmental fracture. This type also includes open fractures caused by farm injuries, fractures requiring vascular repair or fractures that have been open for 8 hr. prior to treatment.
III A	Type III fracture with adequate periosteal coverage of the fracture bone despite the extensive soft tissue laceration or damage.
III B	Type III with extensive soft tissue loss and periosteal stripping and bone damage. Usually associated with massive contamination. will often need further soft tissue coverage procedure (i.e., free or rotational flap)
III C	Type III fracture associated with an arterial injury requiring repair, irrespective of degree of soft tissue injury

Table 2

MATERIALS AND METHODS

This is a prospective study, which was carried out in the Department of Orthopaedics in Shadan Institute of Medical Sciences, Teaching Hospital and Research Centre, Hyderabad, Telangana, India during November 2021 to November 2023.

Inclusion Criteria

1. All patients are within the age group more than 18 years.
2. All closed extra articular distal tibia fractures as per AO classification 43A1,43A2,43A3 with Tsherene and Oestern grade 0 and grade 1.
3. Gustilo and Anderson Type 1.

Exclusion Criteria

1. Age below 18 years.
2. Intra articular extension of fracture.
3. Gustilo and Anderson Type 2 and 3.
4. All pathological fracture.
5. Patient not willing for surgery.
6. Patient medically unfit for surgery.

General information like name, age, sex, occupation and address were noted. Then a detailed history was elicited regarding mode of injury, Road traffic accident, direct injury to leg and ankle. Enquiry was made to note site of pain and swelling over the affected leg. Past medical illness and family history were also recorded.

General condition of the patients was examined for pallor, pulse rate and blood pressure. Respiratory and cardio vascular system were examined for any abnormalities.

Local examination was done in the following steps:

1. On inspection the following points were noted. Abnormal swelling was present in the leg and foot fracture. The condition of the skin over the distal one third tibia was noted for any abrasion, laceration and contusion.
2. On palpation the following points were noted: Palpation of the entire length of the affected tibia and fibula shows tenderness over fracture. The fractured tibia and fibula was also palpated for any abnormal mobility and crepitus.
3. Movements: The movements of the affected side ankle were restricted due to pain.

The distal neurovascular status of the affected lower limb was examined and also the associated injuries along with fractured tibia and fibula were noted. Plain radiograph of entire tibia and fibula with ankle in anteroposterior view was taken to assess the site of fracture and the fracture type(displacement and comminution). The fractures were classified according to AO classification. The affected lower limb was immobilized in above knee slab. Routine investigation like Hb%, Total count, Differential count, ESR, Blood urea, Sugar, Serum creatinine, blood grouping typing and ECG were done. HbsAg and HIV test were done before surgery on all patients. All patients were operated as early as possible once the general condition of the patients were stable and the patients were fit for surgery as assessed by the physician.

Preoperative preparation of patients:

- Patients were kept fasting for 6 hours before surgery.
- A written informed consent for surgery was taken.
- The parts were prepared.
- Xylocaine test dose were given and noted if any hypersensitivity reaction occurred.

©2024Int. J. LifeSci.Biotechnol.Pharma.Res.

DOI: 10.69605/ijlbpr_13.6.2024.57

- Injection tetanus toxoid stat dose.
- Tranquilizers were given as advised by the anesthetist.
- A systemic antibiotics usually inj. Cefperazone and salbactum 1.5gm intravenously were administered 30 minutes before surgery to all patients.

All patients were operated under Spinal anesthesia.

Instruments used for Locking plate fixation:

• 4.5mm Locking Compression Plate. • 2.7 mm drill bit • 3.5mm universal drill guide. • Manmann drill • 3.5mm Tap for cortical screw • Depth gauge • 3.5mm cortical screw of varying sizes (12-22mm). • Hexagonal screw driver. • General orthopedic instruments like retractor, periosteal elevator, reduction clamps and bone lever.

TECHNIQUE FOR PLATE AND SCREW FIXATION

- Position-supine with affected leg elevated on a pillow/sand bag.
- Pneumatic tourniquet applied, time and pressure noted.

Surgical technique:

Plate selection:

- The plates are available in various lengths and configurations similar to the Synthes Small.
- If necessary, use a bending template to determine plate length and configuration.
- Use the bending instruments to contour the Locking Compression Plate to the anatomy.

Reduction and plate placement:

- The fracture is reduced preliminarily by manual traction and use of pointed reduction forceps. Adequate reduction of the fracture is confirmed using an image intensifier.
- A small longitudinal incision is made for plate insertion at the level of tibial plafond and extended proximally. A premeasured and precontoured metaphyseal LCP is inserted, using the threaded drill guide as a handle, into the subcutaneous tunnel and the fracture is reduced and position of plate confirmed under fluoroscopic guidance.

Another incision is made at the proximal end of the plate, position confirmed visually and the plate was fixed with two k wires provisionally both proximally and distally.

- First screw is inserted at the distal end of the plate close to the joint line and the second screw is inserted at the proximal end of the plate percutaneously. After confirming fracture reduction using image intensifier, a lag screw is inserted through the plate to reduce the fracture gap. Locking screws were inserted in the mid-section of the plate.

Screw insertion: Determine whether standard cortex screws, cancellous screws or 5 mm locking screws will be used for fixation. A combination of all may be used.

Insertion of a cortex or cancellous bone screw Use the 3.5 mm Universal Drill Guide for an eccentric (compression) or neutral (buttress) insertion of cortex screws.

Neutral insertion of a standard screw.

When pressing the universal drill guide into the DCU (Dynamic Compression Unit) portion of the LCP plate, it will center itself and allow neutral pre drilling. Dynamic compression, eccentric insertion of a cortex screw.

To drill a hole for dynamic compression, place the universal drill guide eccentrically at the edge of the DCU portion of the LCP plate hole, without applying pressure. Tightening of the cortex screws will result in dynamic compression corresponding to that of the LC-DCP.

Since the direction of a locking screw is determined by plate design, final screw position may be verified with a K-wire prior to insertion. This becomes especially important when the plate has been contoured or applied in metaphyseal regions around joint surfaces.

Indirect method of reduction of fracture under imagine intensifier can be difficult on a few occasions. No calcaneal pins or mechanical distractors were used in our present series. 3mm k wires and reduction forceps were used to facilitate proper reduction in difficult cases.

No secondary procedures like percutaneous bone marrow injection /bone grafting were done for delayed union. Immobilization was continued for these cases till fracture union was seen.

Blisters were common features when the injury – hospital interval was > 3 days. Tight osteopathic bandage and even non splintage of the fracture also contributed.

The protocol of fixation was early as possible considering the gross swelling and fracture blisters. However this delay did not have bearing on the duration of fracture union which was at an average of 16-18 weeks as comparable to other studies[27].

No cases of injury to the saphenous nerve and the posterior tibial tendon were observed. Injury to atraumatic placement of the drill sleeve and careful attention towards skin incision, tunneling prevents these complications.

No plates and screws were removed in this series and hence the difficulty encountered in the removal were not studied.

The present study is a prospective study of 25 cases of extra articular distal 1/3rd tibia fractures (AO Type 43A1, 43A2, 43A3 with Tsherene and Oestern grade 0 and grade 1), of which 16 male and 9 female ranging from 18 to 80 treated by open and reduction and internal fixation, which was conducted over a period of 1 year. Case wise detailed study was done in all cases by nothing the age, sex, social status, nature of trauma, duration of the injury and information

©2024Int. J. LifeSci.Biotechnol.Pharma.Res.

DOI: 10.69605/ijlbpr_13.6.2024.57

regarding medical problems and any local problems in relation to bone and joints. On admission, emergency care was given with special attention airway, breathing and circulation. A thorough systematic examination is done to rule out other injuries. They were examined for signs of fractures, deformity and any compromise of distal neurovascular status. On inspection the following points were noted. Abnormal swelling was present in the leg and foot fracture. The condition of the skin over the distal one third tibia was noted for any abrasion, laceration and contusion. On palpation the following points were noted: Palpation of the entire length of the affected tibia and fibula shows tenderness over fracture. The fractured tibia and fibula was also palpated for any abnormal mobility and crepitus. Movements: The movements of the affected side ankle were restricted due to pain.

Criteria taken are history, clinical and radiological. All people between 18 - >60years who had AO type 43A1, 43A2, 43A3.

1. Five cases were associated with other injuries such as fibula fracture, head injury, chest injury, Proximal tibia fracture. No vascular injuries were noted in this series.
2. The average time between admission and operation was 5-6 days. And in patients with severe blood loss and in hypovolemic shock, it was corrected with intravenous fluids and blood.
3. In case of compound fractures wound was debrided thoroughly and wash was given with normal saline, hydrogen peroxide, betadine and if wound was smaller, primary closure was done. All the cases were initially treated with above Knee Plaster of Paris slab, all compound wounds healed well without causing infection. All compound fractures were covered with Injection Tetanus Toxoid and combination of antibiotics consisting of cephalosporins, aminoglycosides and metronidazole and this regimen effectively prevented infection. For simple fractures antibiotic regimen was started 12 hours before surgery parenterally and continued till third postoperative day, from then till 10th day post-operative oral preparation was given.
4. Other fractures and injuries were attended depending upon the priority order and were treated on standard principles and guidelines. All patients were taken up for surgery when general condition was stable under spinal anaesthesia or Femoral Block. The implant used was anatomically pre-contoured 4.5 mm extra-articular distal Locking Compression Plate
5. Patients were kept in postoperative ward for first 48 hours and then shifted to respective general ward. On 2nd post-operative day drain was removed and antiseptic dressing was done. Post-operative check X-ray was taken.
6. Bed side exercises (active assisted and gravity assisted exercises) were started as early as possible depending on the condition of patient and stability of fracture fixation. Suture removal was done on 10th post-operative day and patient was discharged with advice of active assisted exercises and physiotherapy. Follow up was 3 weeks until time of radiological union and monthly till the end of follow up.
7. During the follow up patients were received in outpatient department once in every 3 weeks and fracture union was assessed clinically and radiologically.
8. The follow up period ranges between 20 weeks to 40 weeks with average of 7 months and patients were assessed for functional capacity and radiological fracture healing capacity periodically every 4 – 6 weeks.
9. The functional outcome was assessed by Oleaur & Mollander scoring system[15].

INTRAOPERATIVE PICTURES

Fig 2

Fig 3

©2024Int. J. LifeSci.Biotechnol.Pharma.Res.

Online ISSN: 2250-3137
Print ISSN: 2977-0122

DOI: 10.69605/ijlbpr_13.6.2024.57

Fig 3

Fig 4

RESULTS

The present study consists of 25 patients of fresh fracture of the lower 1/3rd extra articular tibia and fibula which were treated surgically with locking compression plate Department of Orthopaedics in Shadan Institute of Medical Sciences, Teaching Hospital and Research Centre, Hyderabad, Telangana, India during November 2021 to November 2023.

All the patients were available for follow-up and they were followed every 6 weeks. Results were analyzed both clinically and radiologically.

Table 3: Distribution of patients based on Age

Age distribution	No. of patients	Percentage
18-30yrs.	2	8
31-40yrs.	5	20
41-50yrs.	12	48
51-60 yrs.	5	20
>60 yrs.	1	4
Total	25	100

Table 3: Based on Sex

Sex	No. of patients	Percentage
Male	16	64
Female	9	36
Total	25	100

Table 4: Based on AO Classification – Extra Articular Fracture

AO Classification	No. of patients	Percentage
A1 – Simple	12	48
A2 – Wedge	10	40
A3 – Complex	3	12
Total	25	100

Table 5: Mechanism of Injury

Mechanism of Injury	No. of patients	Percentage
RTA	18	72
Accidental Fall	7	28
Total	25	100

©2024Int. J. LifeSci.Biotechnol.Pharma.Res.

Online ISSN: 2250-3137
Print ISSN: 2977-0122

DOI: 10.69605/ijlbpr_13.6.2024.57

Table 6: Fracture Characteristics

Type	No. of patients	Percentage
Closed	22	88
Open	3	12
Total	25	100

Table 7: Side Affected

Side Affected	No. of patients	Percentage
Left	11	44
Right	14	56
Total	25	100

Table 8: Time to Radiological Union

Time to Radiological Union	No. of patients	Percentage
<14 weeks	5	20
14-16 weeks	14	56
17-19 weeks	4	16
20-22 weeks	2	8
Delayed union	0	0
Non-union	0	0
Total	25	100

Table 9: Outcome

Outcome	No. of patients	Percentage
Excellent	13	52
Good	6	24
Fair	4	16
Poor	2	8
Total	25	100

Table 10: Complications Observed

Complication	No. of patients	Percentage
None	23	92
Delayed union	0	0
Superficial Wound Infection	2	8
Total	25	100

FIG 5 (PRE-OP)

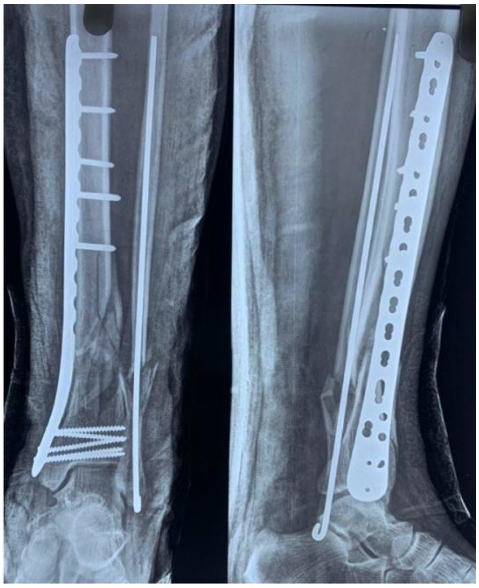

FIG 6(Immediate postop)

©2024Int. J. LifeSci.Biotechnol.Pharma.Res.

DOI: 10.69605/ijlbpr_13.6.2024.57

FIG 7 (1month follow up)

FIG 8 (6 Month follow up)

DISCUSSION

The optimal treatment of unstable distal tibia without articular involvement remains controversial, despite the variety of treatment options which have been suggested for these injuries, including nonoperative treatment, external fixation, intramedullary nailing, and plate fixation. However, each of these treatment options has certain defects. Nonoperative treatment may be complicated by loss of reduction and subsequent malunion; external fixation of distal tibia fractures may result in insufficient reduction, malunion, and pin tract infection; there is some concern about the use of IMN in distal tibia fractures; ORIF results in extensive soft tissue dissection and may be associated with wound complications and infections. Distal tibial fractures remain one of the most substantial therapeutic challenges that confront the orthopaedic traumatologist.

In recent years, numerous reports have argued that the MIPO technique is a safe and worthwhile method of managing such fractures, whilst avoiding some of the complications associated with conventional open plating methods[26].

Concomitant fibula fracture at the same level plays an important role in reduction. Authors advocate fixation of distal fibula fracture fixation before fixation of the tibia to achieve a better alignment and to prevent valgus/varus malalignment, no clear-cut indication/ protocol exists as far as fibula fracture fixation is considered.

Routine fixation of the distal fibula fracture was done in the present study. No secondary procedures like percutaneous bone marrow injection /bone grafting were done for delayed union. Immobilization was continued for these cases till fracture union was seen.

The present study was under taken to determine the efficacy of the locking compression plates in treatment of the fractures of the distal tibial metaphysis using MIPO technique.

We evaluated our results and compared them with those obtained by various other studies utilizing different modalities of treatment, our analysis is as follows: In the present study, the mean age of 45.5 years is comparable to the studies by Bahari et al.[16] and Redfern, Syed, Davies[17]. The age of the patient had no bearing on the time to union in our study.

In our study, there were associated injuries in 21 patients (84%). We have stabilized distal fibula where fracture site was 5 cm above articular surface. It provides satisfactory alignment. The fracture middle and upper one third fibula was not fixed. The operated fracture tibia united at 17 weeks. Because of the associated fractures, mobilization was delayed but all tibia united at 22 weeks.

Concomitant fibula fracture at the same level plays an important role in reduction. Authors advocate fixation of distal fibula fracture fixation before fixation of the tibia to achieve a better alignment and to prevent valgus/varus malalignment, no clear cut indication protocol exists as far as fibula fracture fixation is considered. According to Deebak kumar[18] et al Concurrent fibula fixation with plate osteosynthesis will minimise the incidence of malunion for distal tibia fractures.

The present study was under taken to determine the efficacy of the locking compression plates in treatment of the fractures of the distal tibial metaphysis using mipo technique. We evaluated our results and compared them with those obtained by various other studies utilizing different modalities of treatment, our analysis is as follows:

Our study revealed the average age of patients with such injuries to be 45.5 years (18-65).

In our study, the male preponderance for such kind of injuries were high 60% compared to the study by Cory collinge et al[19] and the study by Ovadia and Beals which had 67% male patients.

©2024Int. J. LifeSci.Biotechnol.Pharma.Res.

DOI: 10.69605/ijlbpr_13.6.2024.57

Our present study correlates with the study conducted by Cory Colling al[17], Andrew Grose et al[21] , and along with that Heather A. Vallier et al[20] , who contributed only 51% of high energy fractures.

We had a higher percentage of type A fracture due to the selection process based on the aim of the study.

However, study by Cory collinge et al[19] showed 16% C1, 32% C2 and 24% C3. Andrew Grose[21] et al also had fractures types 2% B1, 4% B2,12% B3, 6% C1, 12% C2, 64% C3. Heather A Vallier et al also had fractures 31% A, 21% B, 44% C.

The average surgical time was 84 minutes.

The average time for fracture union in various studies conducted using various methods was 16-28 weeks. Our study had an average fracture union of 17 weeks which were comparable with studies conducted using the locking compression plates. Cory Collinge et al[19] had an average fracture union of 21weeks and Abid Mushtaq et al[22] had an average of 22 weeks.

In the present study clinical results were evaluated according to the AOFAS score chronologically and at union. On union, all of the 25 patients had an AOFAS score of 90 or greater out of a possible 100 points. The mean score was 95.06.

Collinge and Protzman[23] reported a good to excellent result with a mean AOFAS score of 85. In the study undertaken by Redfern et al[17] all patients returned to their pre-injury occupation or level of activity. The mean AOFAS score in the MIPO group of the study by J J Guo et al[46] was 83.9. Vasu Pai, Gareth Coulter and Vishal Pai[25] in their study of minimally invasive plate fixation of the distal tibia reported excellent results in11 patients, good in 9, fair in 2 and poor result in one patient.

CONCLUSION

- Distal one third extra articular fractures usually require operative management because they are usually present with rotation as well as varus angulation. Stabilization with cast require prolonged immobilization.
- Among the internal fixation methods intramedullary fixation do not control rotation if nail is not locked in two planes. They require longer period of immobilization till union.
- In this study primary closed reduction and internal fixation with LCP or MIPO of fresh distal third tibia fractures provide a more rigid fixation and does not require immobilization for longer periods.
- All the fractures united and there was no nonunion.
- Implant removal was not done till the end of this study so result.
- Anterolateral locking compression plate for distal tibia recently introduced which is consider to better option because it does not cause hardware prominence.
- Polyaxially locking compression is another choice for the distal tibia fracture

REFERENCES

1. Im GI, Tae SK. Distal metaphyseal fractures of tibia: a prospective randomized trial of closed reduction and intramedullary nail versus open reduction and plate and screws fixation. J Trauma. 2005; 59:1219– 1223. [PubMed] [Cross Ref]
2. Janssen KW, Biert J, Kampen A. Treatment of distal tibial fractures: plate versus nail: a retrospective outcome analysis of matched pairs of patients. Int Orthop.2007;31:709–714. [PMC free article] [PubMed][Cross Ref]
3. Ronga M, Shanmugam C, Longo UG, Oliva F, Maffuli N. Minimally invasive osteosynthesis of distal tibia fracture using locking plates. Orthop Clin North Am.2009 Oct;40(4):499-504[PubMed] [Cross Ref]
4. Farouk O, Krettek C, Miclau T, Schandelmaier P, Guy P, Tscherne H. Minimally invasive plate osteosynthesis and vascularity: preliminary results of a cadaver injection study. Injury. 1997;28(Suppl 1): A7–A12. [PubMed] [Cross Ref]
5. Borrelli J, Prickett W, Song E, Becker D, Ricci W. Extraosseous blood supply of the tibia and effect different plating techniques: human cadaveric study Orthop Trauma 2002nov-dec;16(10):691-5[PubMed] [Cross Ref]
6. Hong Gao; Ching – Quing Zhang; Cong Feng Luo; Zu-Bhin-Zhou; Bing-Fang Zing; Clinical Orthopaedics and related research Vol: 467(3), March 2009:831-37
7. John Charnley. The closed treatment of common fractures. Cambridge. Colt Books Ltd., 1999.
8. Egol KA, Kubiak EN, Fulkerson E, Kummer FJ, Koval KJ. Biomechanics of locked plates and screws. J Orthop Trauma. 2004; 18:488–93.
9. Kaab MJ, Frenk A, Schmeling A, Schaser K, Schutz M, Haas NP. Locked internal fixator: sensitivity of screw/plate stability to the correct insertion angle of the screw. J Orthop Trauma. 2004; 18:483–87.
10. stevens C, Le T, Archdeacon MT, Wyrick JD. Management of extraarticular fractures of the distal tibia: intramedullary nailing versus plate fixation. J Am Acad Orthop Surg. 2012
11. Tscherne H, Oestern HJ.A new classification of soft-tissue damage in open and closed fractures (author's transl)]. Unfallheilkunde. 1982 Mar;85(3):111-5.
12. McFerran MA, Smith SW, Bonlas HJ. Complications encountered in the treatment of pilon fractures. J Orthop Trauma 1992; 6: 195-200.
13. Tscherne H, Oestern HJ.A new classification of soft-tissue damage in open and closed fractures (author's transl)]. Unfallheilkunde. 1982 Mar;85(3):111-5.
14. Gustilo RB, Anderson JT. Prevention of infection in the treatment of one thousand and twenty-five open fractures of long bones: Retrospective and prospective analyses. J Bone Joint Surg Am. 1976;58:453–8
15. Oleaur C, Molander H scoring scale for symptom evalution after ankle fracture. Arch Orthop Trauma Surg 1984;103(3)190-4.
16. Bahari S., Lenehan B., Khan H., Mcelwain J.P. Minimally invasive percutaneous plate fixation of distal tibia fractures. Acta Orthop Belg. 2007; 73:635–40.
17. Redfern D.J., Syed S.U., Davies S.J.M. Fractures of the distal tibia: minimal invasive plate osteosynthesis. Injury. 2004; 35:615–620.
18. Deebak K, Ganesan GR, Phagal VV. Minimally invasive Plate Versus Intramedullary Interlocking Nailingin Distal Third Tibia Fractures: IOSR Journal

©2024Int. J. LifeSci.Biotechnol.Pharma.Res.

DOI: 10.69605/ijlbpr_13.6.2024.57

of Dental and Medical Sciences 2014 Mar (13) issue 3:15-17.

19. Collinge C, Sanders R, DiPasquale T. Treatment of complex tibial periarticular fractures using percutaneous techniques. Clin Orthop Relat Res.2000; 375:69-77. aofos score.
20. Heather .A. Vallier, T. Toan le, Asheesh Bedi. Radiographic and clinical comparisons of distal tibia shaft fractures (4-11 cms proximal to plafond) plating versus intramedullary nailing. J Orthop Trauma 2008; 22:307-11.
21. Andrew Grose, Michael. J. Garden. Open reduction and internal fixation of tibial pilon fractures using a lateral approach. J. Orhop Trauma 2007; 21:530-7.
22. Abid Mushtaq, Rizwan S,Muhammad A, Mohammad M, Distal Tibial Fracture Fixation with Locking Compression Plate (LCP) Using the Minimally Invasive Percutaneous Osteosynthesis (MIPO) Technique European Journal of Trauma and Emergency Surgery 2008 May;35(2):159- 64.
23. Cory C, Robert Protzman. Outcomes of minimally invasive plate osteosynthesis for metaphyseal distal tibial fractures. J. Orthop Trauma 2010; 24:24-29.
24. Guo J., Tang N., Yang H.L., Tang T.S. A prospective, randomized trial comparing closed intramedullary nailing with percutaneous plating in the treatment of distal metaphyseal fractures of the tibia. J Bone Jt Surg Br. 2010;92-B:984–8. [PubMed].
25. Pai V, Coulter Gareth, Pai V. Minimally invasive plate fixation of the tibia.Int Orthop. 2007;31(4):491–496. [PubMed].
26. Maredza M, Petrou S, Dritsaki M, et al. A comparison of the cost-effectiveness of intramedullary nail fixation and locking plate fixation in the treatment of adult patients with an extra-articular fracture of the distal tibia: economic evaluation based on the FixDT trial. Bone Joint J. 2018; 100-B (5): 624 – 633.
27. Wenger R, Oehme F, Winkler J, Perren SM, Babst R, Beeres F. Absolute or relative stability in minimal invasive plate osteosynthesis of simple distal meta or diaphyseal tibia fractures. *Injury*. 2017; 48:1217–1223.

©2024Int. J. LifeSci.Biotechnol.Pharma.Res.