

**ORIGINAL RESEARCH**

# Primary and Secondary Disseminated Hydatid Disease: Radiological and Clinical Features

<sup>1</sup>Dr. Sumaya F. Shad, <sup>2</sup>Dr. Geetanjali Gupta, <sup>3</sup>Dr. Neetu Jamwal, <sup>4</sup>Dr. Shyam Kumar Gupta, <sup>5</sup>Dr. Davinderpal Singh

<sup>1</sup>MBBS, M.S Surgery, Department of General Surgery, GMC, Jammu, Jammu and Kashmir, India Orcid 0000-0002-2646-0254

<sup>2</sup>Senior Consultant and Head Radiology, SMVDNSH Kakryal, Katra, Jammu and Kashmir, India Orcid 0000-0003-1805-5459

<sup>3</sup>Post graduate resident, Department of General Surgery, GMC, Jammu, Jammu and Kashmir, India Orcid 0009-0001-0685-5793

<sup>4</sup>MS MRCS FRCS (Glasgow), Department of General Surgery, GMC, Jammu, Jammu and Kashmir, India Orcid 0000-0003-1896-0328

<sup>5</sup>Post graduate resident, Department of General Surgery, GMC, Jammu, Jammu and Kashmir, India Orcid 0009-0004-4871-6187

**Corresponding Author**

Dr. Sumaya F. Shad

MBBS, M.S Surgery, Department of General Surgery, GMC, Jammu, Jammu and Kashmir, India Orcid 0000-0002-2646-0254

**Email:** [shad.sumaya@gmail.com](mailto:shad.sumaya@gmail.com)

Received date: 19 April, 2024

Acceptance date: 21 May, 2024

**ABSTRACT**

**Introduction:** Hydatid disease(HD), caused by the parasitic infestation of *Echinococcus granulosus*, is endemic in India. While hepatic(59-75%) and pulmonary (27%) involvement is common, primary and secondary disseminated hydatid disease (PDHD, SDHD) present unique clinical and radiological features necessitating a comprehensive understanding for accurate diagnosis and management. SDHD, resulting from peritoneal implantation due to traumatic/ surgical rupture of the cyst is uncommon. PDHD accounting for 2% of intra-abdominal hydatidosis, is even rarer. **Methods:** A retrospective study of 45 patients from 1-12-2022 to 01-12-2023 at GMCH Jammu and SMVD Narayana Hospital, aimed to investigate the clinical and radiological features of HD across different organ systems. The study highlights the diverse clinical presentations and radiological findings associated with disseminated HD. These findings contribute to a better understanding of the diagnostic and management strategies for this condition. **Results:** Most common symptoms were abdominal lump and vague abdominal pain. Radiological imaging, primarily ultrasound and CT scans, facilitated diagnosis. SDHD was more common in females( male-to-female ratio of 1:2). **Conclusion:** Disseminated HD, although rare, warrants attention due to its potential multi-organs involvement. Early recognition and accurate radiological assessment are crucial for effective management. Further research is warranted for comprehensive understanding.

**Keywords:** Hydatid disease, *Echinococcus granulosus*, Parasitic infestation, Disseminated hydatidosis, Abdominal hydatidosis

This is an open access journal, and articles are distributed under the terms of the Creative Commons Attribution- Non Commercial-Share Alike 4.0 License, which allows others to remix, tweak, and build upon the work non-commercially, as long as appropriate credit is given and the new creations are licensed under the identical terms.

**INTRODUCTION**

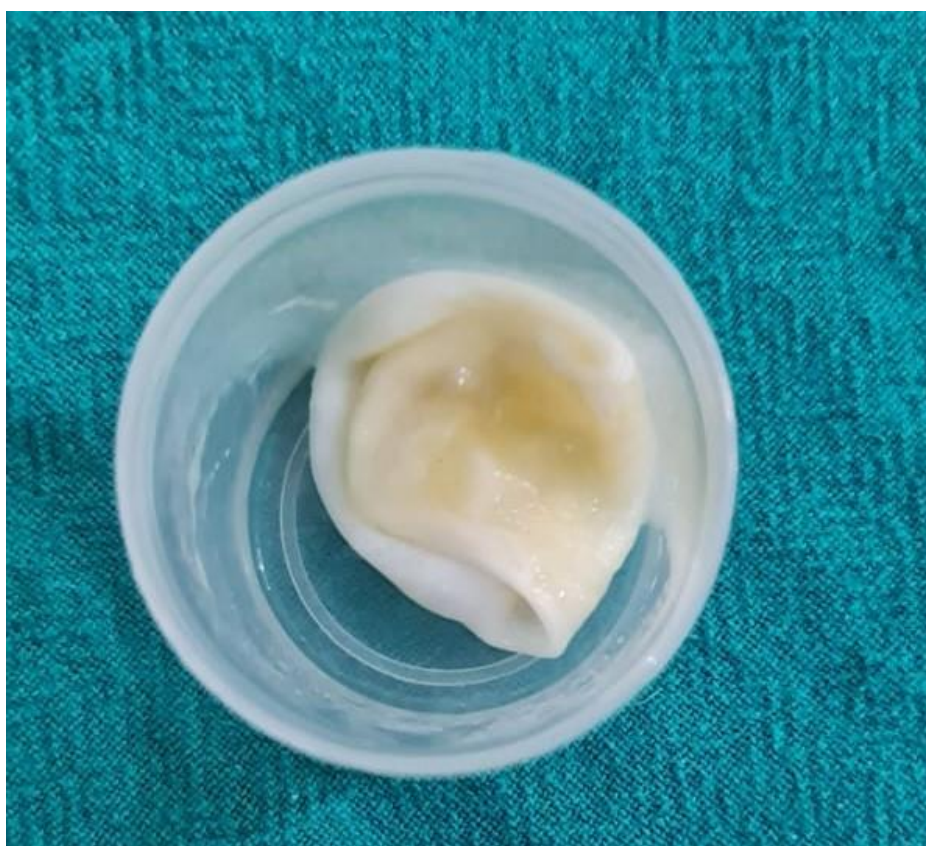Hydatid disease, caused by the parasitic infestation of *Echinococcus granulosus*, presents a formidable challenge to public health systems, particularly in regions where it is endemic, such as India. This zoonotic infection is transmitted primarily through contact with infected canines or ingestion of contaminated food or water [1]. The parasite's complex life cycle involves definitive hosts, typically

canines, and intermediate hosts, including humans and various herbivores. Within the intermediate host, the larvae develop into hydatid cysts, which can grow gradually and produce protoscoleces, the infective form of the parasite, thereby perpetuating the cycle [2]. While hydatid disease primarily affects the liver, accounting for the majority of cases, it can also involve other organs, leading to diverse clinical presentations and complications [3,10]. In addition to

the liver, hydatid cysts may develop in the lungs, kidneys, bones, brain, and other sites, posing significant diagnostic and therapeutic challenges [3,4,8]. The propensity of hydatid cysts to disseminate within the abdominal cavity, either through spontaneous or iatrogenic rupture, adds another layer of complexity to its clinical course [4,5]. The epidemiology of hydatid disease varies globally, with higher prevalence rates reported in rural areas where humans and animals coexist in close proximity [3]. In India, the disease burden is substantial, with several studies highlighting its endemic nature in certain regions [6,7]. Factors such as poor sanitation, limited access to healthcare facilities, and close contact with domestic animals contribute to the persistence of this parasitic infection [6,7]. Understanding the clinical spectrum and radiological features of hydatid disease,

particularly disseminated forms involving multiple organ systems, is crucial for timely diagnosis and effective management. Symptoms vary based on the involved organs, ranging from asymptomatic to life-threatening complications such as anaphylaxis or organ dysfunction. Despite advancements in diagnostic modalities and treatment strategies, challenges persist in accurately identifying and treating disseminated hydatid disease, necessitating ongoing research efforts to improve outcomes and reduce morbidity and mortality associated with this condition [3,5,9].

The objective of the research is to study the clinical signs and symptoms of PDHD and SDHD to aid in early diagnosis and management and also to explore various diagnostic techniques in order to enhance patient care.



**Fig.1 Hydatid cyst spontaneously released per urethra by a patient with disseminated hydatosis involving urinary bladder.**

## **MATERIALS AND METHODS**

**Study Design:** This retrospective study was conducted on 45 patients diagnosed with disseminated hydatid disease at Government Medical College Hospital Jammu and SMVD Narayana Hospital, spanning the departments of surgery and radiodiagnosis. Data were collected from medical records and imaging reports.

Ethical approval to conduct the research was given by Institutional Ethics Committee Government Medical College Jammu

105 patients were considered for the study, out of which 45 patients met the criteria at 95% interval and 80% power of test. Prevalence of the disease was 5%.

### **Inclusion Criteria:**

Patients included in the study met the following criteria:

Presentation with disseminated peritoneal and retroperitoneal hydatosis.

Disease involvement of extra-peritoneal organs.

**Exclusion Criteria:**

Patients with localized hepatic hydatid cysts.  
Patients not giving consent for the study

**Diagnostic Confirmation:** Diagnosis of disseminated hydatid disease was confirmed through a combination of imaging modalities, including abdominal ultrasound, contrast-enhanced computed tomography (CECT), and magnetic resonance imaging (MRI). These diagnostic techniques were utilized to assess the extent of organ involvement and confirm the presence of hydatid cysts.

**Data Collection:** Demographic data, including age, sex, and history of physical contact with animals, were recorded for each patient. Clinical features, duration of hospital stay, and details of surgical and conservative treatments were also documented.

**Data Analysis:** Collected data were analyzed descriptively to characterize the demographic profile, clinical presentation, and management approaches of patients with disseminated hydatid disease. Statistical analysis was not performed due to the small sample size and retrospective nature of the study.

**RESULTS****Demographic Characteristics**

The study comprised 45 patients diagnosed with disseminated hydatid disease, with a male-to-female ratio of 1:2, indicating a higher prevalence of the disease among females.

**Radiological Features**

WHO-IWGE 2001	Gharbi 1981	Description	Stage
CE1	Type I	Unilocular anechoic cystic lesion with double line sign	Active
CE2	Type III	Multiseptated, "rosette-like" "honeycomb" cyst	Active
CE3 A	Type II	Cyst with detached membranes (water-lily-sign)	Transitional
CE3 B	Type III	Cyst with daughter cysts in solid matrix	Transitional
CE4	Type IV	Cyst with heterogeneous hypoechoic/hyperechoic contents. No daughter cysts	Inactive
CE5	Type V	Solid cyst with calcified wall	Inactive

**Table 1: Classification of hepatic hydatid cysts**[17] (CL: cystic lesion, CE: cystic echinococcosis)

Primary dissemination was observed in 9 female and 3 male patients, all without a history of trauma or surgical procedure.

The remaining patients presented with secondary dissemination, one of whom had undergone multiple surgeries for the disease.

**Patient Profile**

The age of the patients ranged from 40 to 70 years, with a mean age of 45 years.

42 patients hailed from rural areas, while only 3 patients resided in an urban area.

History of contact with dogs was reported in 12 patients.

**Clinical Presentation**

The most common presenting features were abdominal lump, pain abdomen, and loss of appetite.

Six patients were incidentally diagnosed and had no abdominal symptoms.

Liver involvement was predominant, with additional organ involvement observed in various cases.

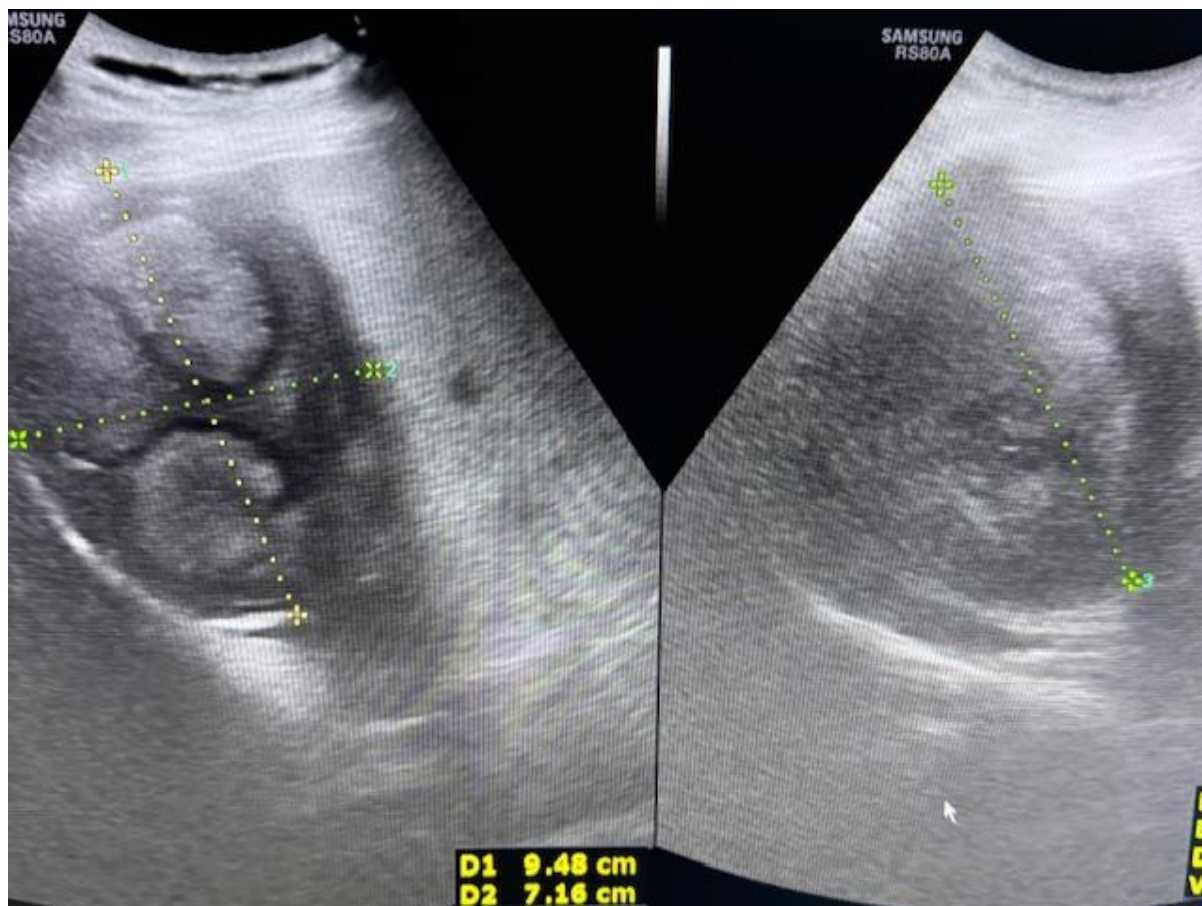
Nine patients had urinary bladder involvement, while 12 patients presented with retroperitoneal hydatosis.

Additionally, adenexal involvement was noted in 9 female patients.

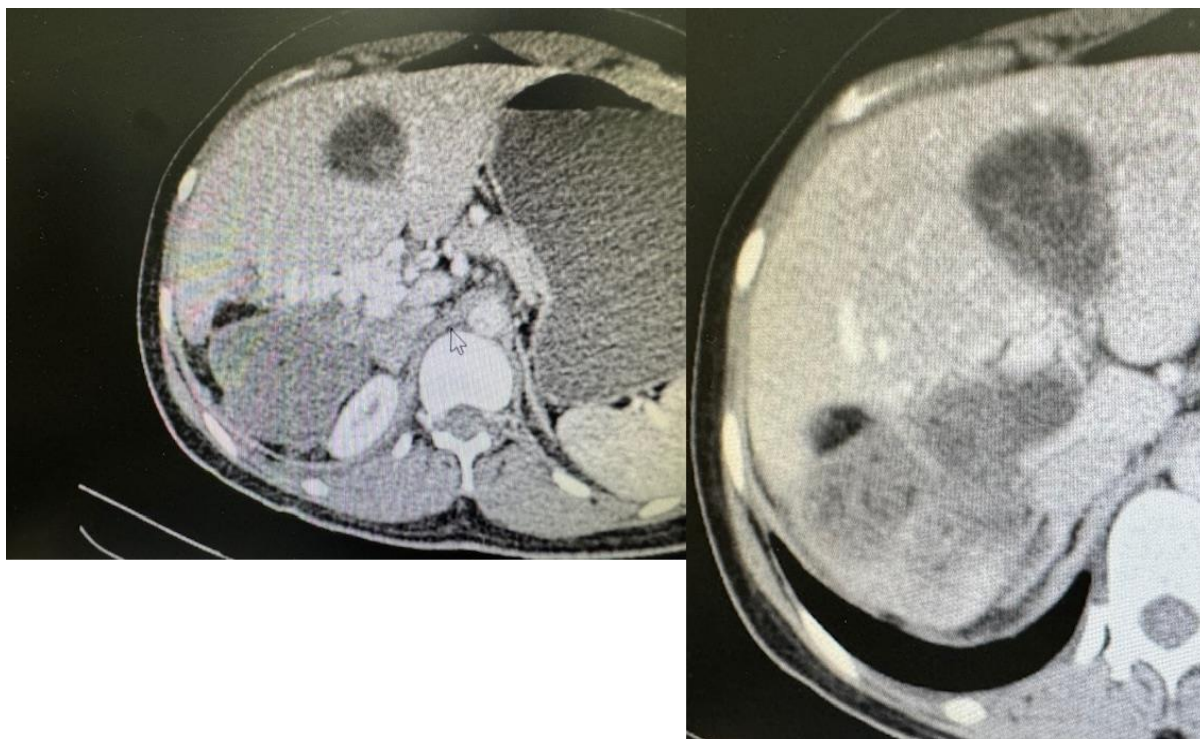
**Treatment**

The majority of patients were managed conservatively with oral Albendazole.

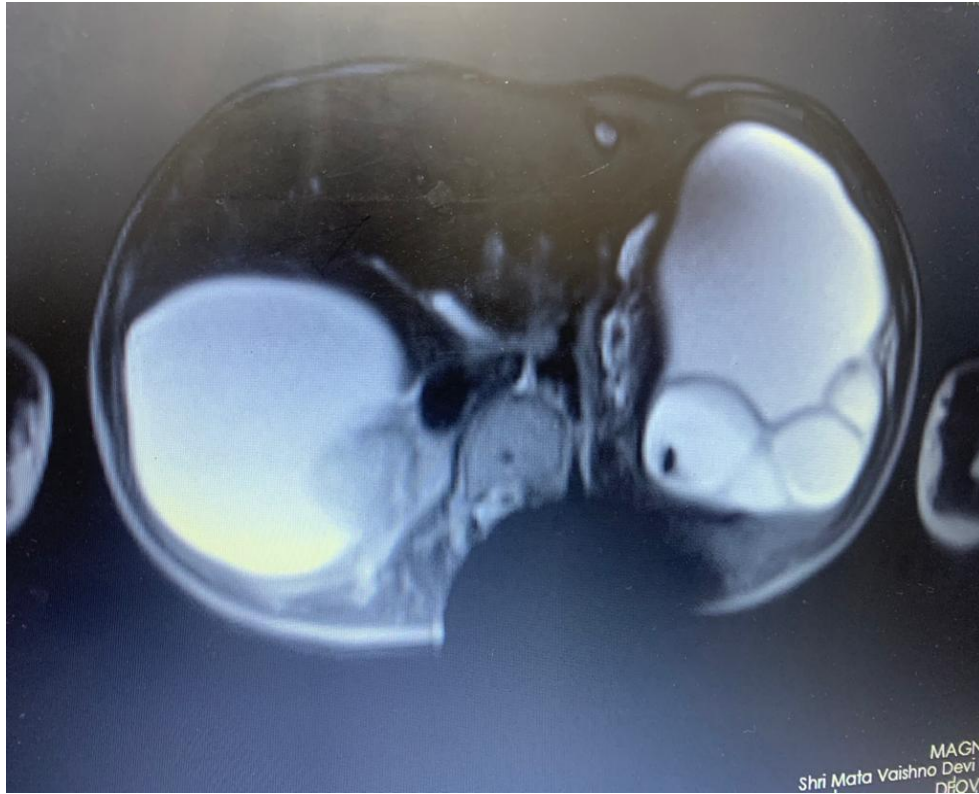
Three patients underwent surgical intervention as part of their treatment approach.



**Fig.2 Sonographic image of a large hepatic cyst with multiple intracystic daughter cysts. Internal echoes are also seen with honeycombing appearance**

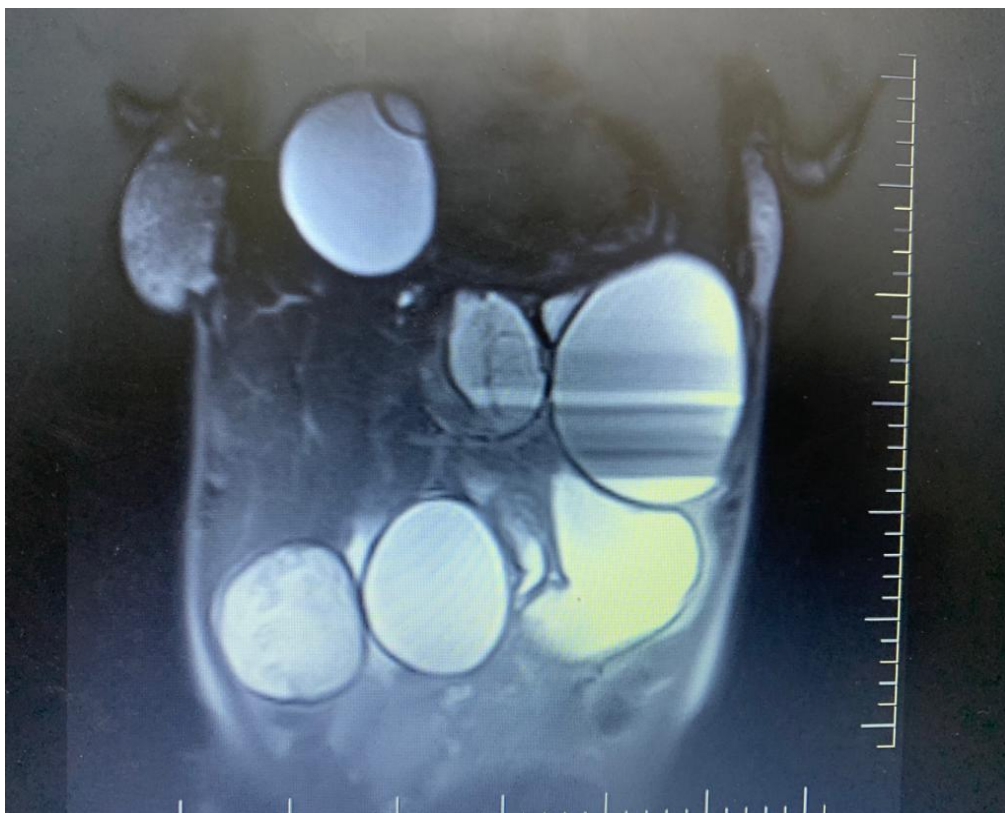


**Fig. 3 Axial CT image: Multiple hepatic hydatid cysts. one cyst appears like a ruptured cyst with Crescent sign representing trapped air between the laminated membrane of the endocyst. Other cysts in the section also reveal multiple internal septae and daughter cysts**

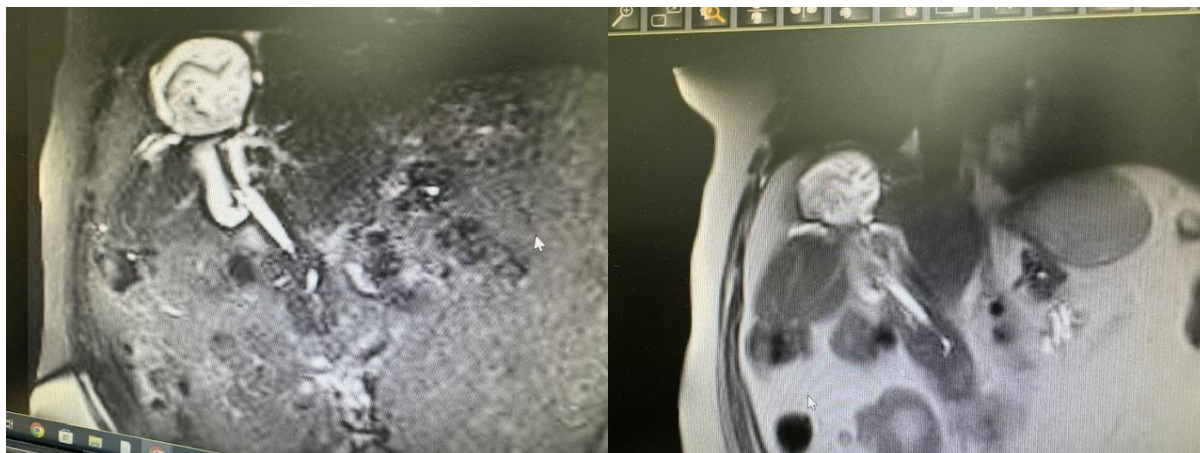


**Fig.4 MRI: Axial T2W image**

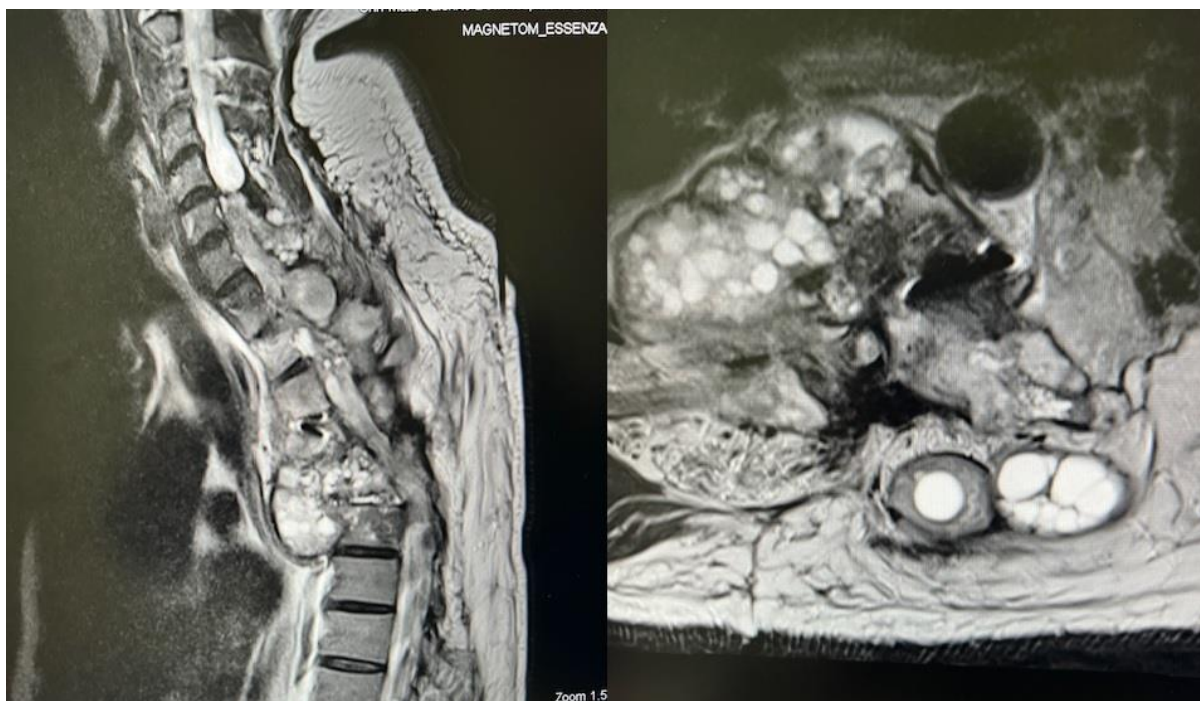**Type II a cyst containing daughter cysts organized at the periphery. Focal hyperintensity represents calcification**



**Fig.5 MRI: Coronal image showing dissemination of hydatid cysts**



**Fig.6 MRI: Axial image of upper abdomen using a fast spin-echo T2-weighted sequence shows a hyperintense linear structures representing detached membranes in the right lobe of liver. There is a hyperintense rim at the periphery and a small cyst wall defect. communication between the cyst and biliary tree is shown with secondary dilatation of biliary tree**



**Fig.7 MRI: T2W axial image of dorsal spine shows multiple spinal and paraspinous hydatid cysts involving the dorsal vertebrae as well as paraspinous soft tissues**

**Mode of presentation and Distribution in patients**

Site	Number of patients	Male	Female	Clinical features	Percentage
Liver + Lung	8	2	6	Lump right hypochondrium Hemoptysis Chronic cough Fever Weight loss	17.77%
Liver + Spleen	9	3	6	Lump abdomen Splénomegaly fever	20%
Liver + Retroperitoneum	12	6	6	Lump abdomen Jaundice Fever Pain abdomen Weight loss	26.66%

Retroperitoneum + Adenexa	9	nil	9	Pain lower abdomen Lump lower abdomen Fever	20%
Liver + Kidney + Urinary Bladder	6	3	3	Lump abdomen Jaundice Pain right hypochondrium Loss of appetite Hepatomegaly Pain in flanks Urinary Retention Pyuria Hematuria Fever Weight loss	13.33%
Liver + Spine	1	1	nil	Lump abdomen Backache Paraplegia Radiculopathy Sphincter dysfunction	2.2%
Total	45	15	30		

**Table.2**

Table 2 provides information on the distribution of hydatid disease in patients according to the affected sites and the gender distribution within those groups.

This table provides insights into the combinations of affected sites in patients with hydatid disease and the gender distribution within those groups.

The clinical features help in recognizing the possible involvement of different organs in hydatid disease based on the symptoms presented by the patients.

## DISCUSSION

Hydatid disease, caused by the cestode *Echinococcus granulosus*, presents a complex clinical challenge due to its variable organ involvement and potential for dissemination [1]. While the liver is the most commonly affected organ, hydatid cysts can also manifest in the lungs, spleen, kidneys, bones, brain, and other sites, posing significant diagnostic and therapeutic challenges [3,4,8,11,16]. Dissemination of hydatid disease can occur via lymphatic or systemic circulation, further complicating management and increasing the risk of multiple organ involvement [13,15].

Primary hydatosis, though rare, presents as an isolated cystic lesion in a single organ, typically requiring surgical intervention for definitive treatment [2,11]. However, disseminated hydatid disease presents a more formidable challenge, often necessitating a multidisciplinary approach for management. In such cases, oral antihelminthic drugs, such as albendazole or mebendazole, play a crucial role in controlling the infection, particularly when surgical intervention is not feasible [3,12,14].

Clinical manifestations of hydatid disease vary depending on the site and organ involved. Common symptoms include abdominal pain, loss of appetite, and malaise. Acute onset of pain may indicate cyst rupture, while fever and jaundice suggest secondary infection or intrabiliary rupture [3,8,16]. Radiological imaging, including ultrasound, computed tomography, and magnetic resonance imaging, play a pivotal role and remain the cornerstone of diagnosis, offering high

sensitivity and specificity in delineating the extent of organ involvement [3,16]. PDHD typically appears as multiple cystic lesions with variable sizes and shapes, exhibiting characteristic daughter cysts within the primary cysts. In SDHD, radiological findings depend on the affected organs, with cystic lesions demonstrating heterogeneous appearances, often accompanied by surrounding inflammatory changes or calcifications.

In our study, dissemination of hydatid disease was more prevalent in females, contrary to the higher incidence observed in males in other studies [7,13]. Rural residents, particularly those involved in cattle farming, were disproportionately affected, highlighting the zoonotic nature of the disease. History of direct contact with dogs was a common finding among infected individuals, emphasizing the importance of preventive measures in animal handling practices [6,7].

This discussion underscores the intricate nature of hydatid disease management, necessitating a comprehensive understanding of its clinical manifestations, diagnostic modalities, and therapeutic approaches to mitigate its impact effectively.

## CONCLUSION

Disseminated hydatid disease represents a rare but challenging manifestation of this parasitic infection, with significant physical and mental burden on affected individuals. Early diagnosis and prompt initiation of treatment are paramount, given the chronic nature of the disease and potential for long-

term complications. Radiological imaging plays a crucial role in diagnosis, enabling timely intervention and management planning.

While surgery remains the mainstay of treatment for primary hydatid disease involving a single organ, disseminated disease poses considerable surgical challenges. Medical management with albendazole and praziquantel emerges as the primary treatment modality in such cases, underscoring the importance of a multidisciplinary approach. With a higher incidence observed in regions like India, hydatid disease should be considered in the differential diagnosis of abdominal lump and chronic abdominal pain, necessitating heightened awareness and vigilance among healthcare providers.

The study has its limitations as PDHD and SDHD are relatively rare conditions. The presentation varies from one patient to the other which complicates the characterization of the disease. Due to the long course of the disease many patients are lost to follow up. It becomes challenging to perform research on large scale to collect sufficient data and get statistically significant results.

**Acknowledgements:** Nil

**Declarations:**

Funding: No funding received

Conflict of interest: None declared

Ethical approval: Approval was obtained from IEC GMC Jammu vide no. IEC/GMCJ/2022/1203

## REFERENCES

- Moro P, Schantz PM. Echinococcosis: a review. *Int J Infect Dis.* 2009 Mar;13(2):125-33. doi: 10.1016/j.ijid.2008.03.037.
- Ankit Kayal, Akhlak Hussain, "A Comprehensive Prospective Clinical Study of Hydatid Disease", *International Scholarly Research Notices*, vol. 2014, Article ID 514757, 5 pages, 2014. <https://doi.org/10.1155/2014/514757>.
- Pedrosa I, Saíz A, Arrazola J, Ferreirós J, Pedrosa CS. Hydatid disease: radiologic and pathologic features and complications. *Radiographics.* 2000 May-Jun;20(3):795-817.
- Kushwaha JK, Sonkar AA, Verma AK, Pandey SK. Primary disseminated extrahepatic abdominal hydatid cyst: a rare disease. *BMJ Case Rep.* 2012 May 30;2012:bcr0220125808.
- Khalili N, Iranpour P, Khalili N, Haseli S. Hydatid Disease: A Pictorial Review of Uncommon Locations. *Iran J Med Sci.* 2023 Mar;48(2):118-129.
- Khuroo MS. Hydatid disease: current status and recent advances. *Ann Saudi Med.* 2002 Jan-Mar;22(1-2):56-64.
- Baruah A, Sarma K, Barman B, Phukan P, Nath C, Boruah P, Rajkhowa P, Baruah M, Dutta A, Naku N. Clinical and Laboratory Presentation of Hydatid Disease: A Study From Northeast India. *Cureus.* 2020 Sep 5;12(9):e10260.
- Rasheed K, Zargar SA, Telwani AA. Hydatid cyst of spleen: a diagnostic challenge. *N Am J Med Sci.* 2013 Jan;5(1):10-20.
- Shabbir M, Ahmed A, Shaikat F, et al. (January 04, 2020) Disseminated Hydatid Disease in a Child Involving Multiple Organ Systems: A Case Report. *Cureus* 12(1): e6564.
- Kosmidis C, Efthimiadis C, Anthimidis G, Vasileiadou K, Koimtzis G, Tzeveleki I, Koletsa T, Prousalidis J, Fahantidis E, Basdanis G, Michalopoulos A, Kesisoglou I. Management of peritoneal hydatid cysts: A forty-year experience. *Heliyon.* 2018 Dec 3;4(12):e00994.
- Czermak, B.V., Akhan, O., Hiemetzberger, R. et al. Echinococcosis of the liver. *Abdom Imaging* 33, 133–143 (2008). <https://doi.org/10.1007/s00261-007-9331-0>.
- Palanivelu C, Jani K, Malladi V, Senthilkumar R, Rajan PS, Sendhilkumar K, Parthasarathi R, Kavalakat A. Laparoscopic management of hepatic hydatid disease. *JLS.* 2006 Jan-Mar;10(1):56-62.
- Canda AE. Disseminated hydatid disease. *Am J Surg.* 2009 Jul;198(1):e3-4.
- Ustianowski AP, Zumla A. Hydatid disease. *Clin Microbiol Infect.* 1998 Jul;4(7):405-409.
- Lianos GD, Lazaros A, Vlachos K, Georgiou GK, Harissis HV, Mangano A, Rauseri S, Boni L, Frattini F, Biondi A, Dionigi G, Katsios C. Unusual locations of hydatid disease: a 33 year's experience analysis on 233 patients. *Updates Surg.* 2015 Sep;67(3):279-82.
- Ilica AT, Kocaoglu M, Zeybek N, Guven S, Adaletli I, Basgul A, Coban H, Bilici A, Bukte Y. Extrahepatic abdominal hydatid disease caused by Echinococcus granulosus: imaging findings. *AJR Am J Roentgenol.* 2007 Aug;189(2):337-43.
- Corona M, Cannavale A, Bruni A, et al. Case report: Percutaneous treatment of multiple honeycomb-like liver hydatid cysts (type III CE2, according to WHO classification). *The Indian Journal of Radiology & Imaging.* 2012 Jan;22(1):23-26. DOI: 10.4103/0971-3026.95399. PMID: 22623811; PMCID: PMC3354352.