

**ORIGINAL RESEARCH**

# Topical Sertaconazole vs topical terbinafine for treatment of Tinea corporis and Tinea cruris

Roohi Sharma<sup>1</sup>, Reeta Gupta<sup>2</sup>, Pavan Malhotra<sup>3</sup><sup>1</sup>Assistant Professor, <sup>3</sup>Professor & Head, Department of Pharmacology & Therapeutics, ASCOMS, Sidhra, Jammu, J& K, India<sup>2</sup>Professor, Department of Dermatology, Venerology and Leprology, ASCOMS, Sidhra, Jammu, J & K, India**Corresponding Author**

Roohi Sharma

Assistant Professor, Department of Pharmacology &amp; Therapeutics, ASCOMS, Sidhra, Jammu, J&amp; K, India

Received: 11 November, 2022

Accepted: 15 December, 2022

**ABSTRACT**

**Background:** Extensive dermatophytic infections and infections of hair and nails which affect the quality of life of people are treated with systemic anti fungals. The present study compared topical sertaconazole and topical terbinafine in management of dermatophytoses. **Materials & Methods:** 92 patients having dermatophytoses of both genders were divided into 2 groups of 46 each. Group I patients were given topical sertaconazole two times daily and group II patients were given topical terbinafine two times daily. Patients were assessed for erythema, scaling, and pruritus. **Results:** There were 26 males and 20 females in group I patients and 24 males and 22 females in group II. Tinea corporis was seen in 24 in group I and 18 in group II and Tinea cruris 22 in group I and 28 in group II. Erythema grade 1 was seen in 12 in group I and 11 in group II, scaling grade 0 was seen in 11 in group I and 12 in group II, pruritus grade 1 in 14 in group I and 16 in group II. The difference was non- significant (P> 0.05). **Conclusion:** Authors found that both drugs found to be equally effective in management of cases of Tinea corporis and Tinea cruris.

**Key words:** Sertaconazole, Terbinafine, Tinea corporis.

This is an open access journal, and articles are distributed under the terms of the Creative Commons Attribution -Non Commercial-Share Alike 4.0 License, which allows others to remix, tweak, and build upon the work non-commercially, as long as appropriate credit is given and the new creations are licensed under the identical terms.

**INTRODUCTION**

“Tinea” refers to scaly fungal infections of the epidermis and skin appendages caused by a group of keratinophilic fungi known as “dermatophytes” which includes three genera, namely, Epidermophyton, Microsporum and Trichophyton. Trichophyton rubrum is implicated as the most common causative agent of dermatophytosis in India.<sup>1</sup> Dermatophytes are group of taxonomically related fungi that invade the keratinized tissue (skin, hair, nails) of humans or other animals resulting in an infection called dermatophytosis. Tinea corporis refers to all dermatophytosis of glabrous skin except the palms, soles and groin. The incidence of topical fungal infections has progressively increased in recent years primarily because of an increased number of immunocompromized patients and the increased use of health clubs and community swimming pools, which favour the spread of infections.<sup>2</sup>

Topical antifungals are routinely used for the treatment of mild dermatophyte infections. Extensive dermatophytic infections and infections of hair and nails which affect the quality of life of people are

treated with systemic anti fungals.<sup>3</sup> The most commonly used topical antifungal agents are Allylamines, Imidazole, Morpholines and Polyenes. Older medications like whitfield ointment, castellani or paint of magenta, gentian violet and undecyclic acid are now replaced by specific agents.<sup>4</sup>

Sertaconazole is an imidazole antifungal agent. It causes inhibition of the synthesis of ergosterol, an essential cell wall component of fungi. Terbinafine exhibits fungicidal action against dermatophytes, Aspergillus species and dimorphic fungi.<sup>5</sup> The present study was conducted with the aim of comparing topical Sertaconazole and topical terbinafine in management of dermatophytoses.

**MATERIALS & METHODS**

The present study was conducted among 92 patients having dermatophytoses of both genders. All were informed regarding the study and written consent was obtained.

Data of patients such as name, age, etc. was recorded. Patients were divided into 2 groups of 46 each. Group I patients were given topical sertaconazole two times

daily and group II patients were given topical terbinafine two times daily. Patients were assessed for erythema, scaling, and pruritis on a 4-point scale (0 = absent, 1 = mild, 2 = moderate and 3 = severe).

Results thus obtained were subjected to statistical analysis. P value less than 0.05 was considered significant.

## RESULTS

**Table I Distribution of patients**

Parameters	Group I	Group II
Drug	2% Sertoconazole	1% terbinafine
M:F	26:20	24:22

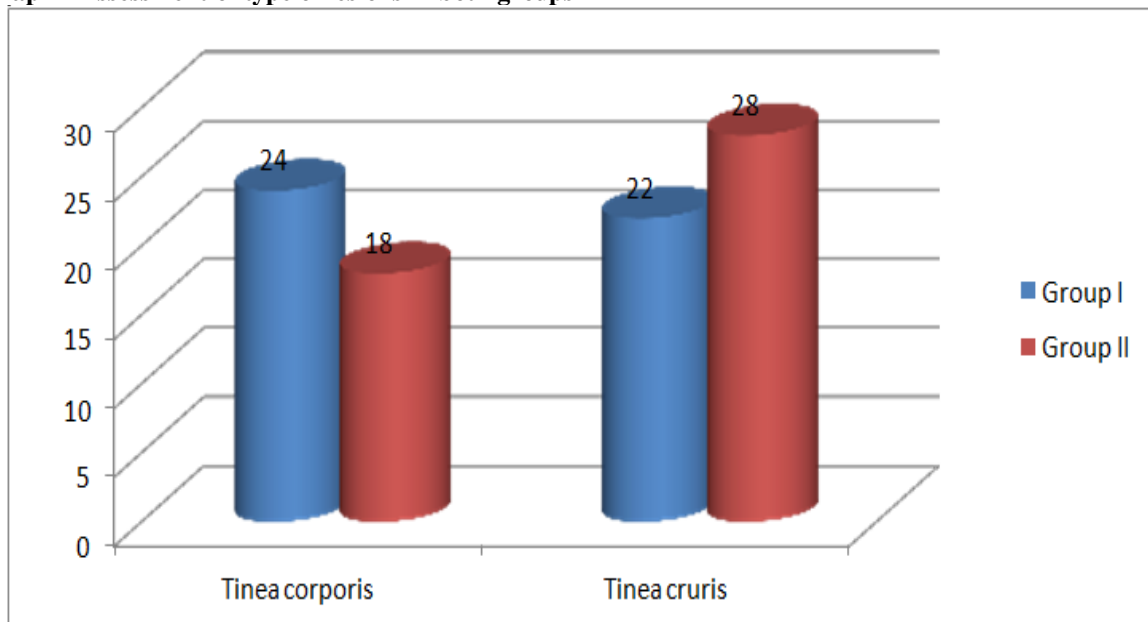
Table I, graph I shows that there were 26 males and 20 females in group I patients and 24 males and 22 females in group II.

**Table II Assessment of type of lesions in both groups**

Lesions	Group I	Group II	P value
Tinea corporis	24	18	0.07
Tinea cruris	22	28	0.08

Table II, graph II shows that Tinea corporis was seen in 24 in group I and 18 in group II and Tinea cruris 22 in group I and 28 in group II. The difference was non- significant ( $P > 0.05$ ).

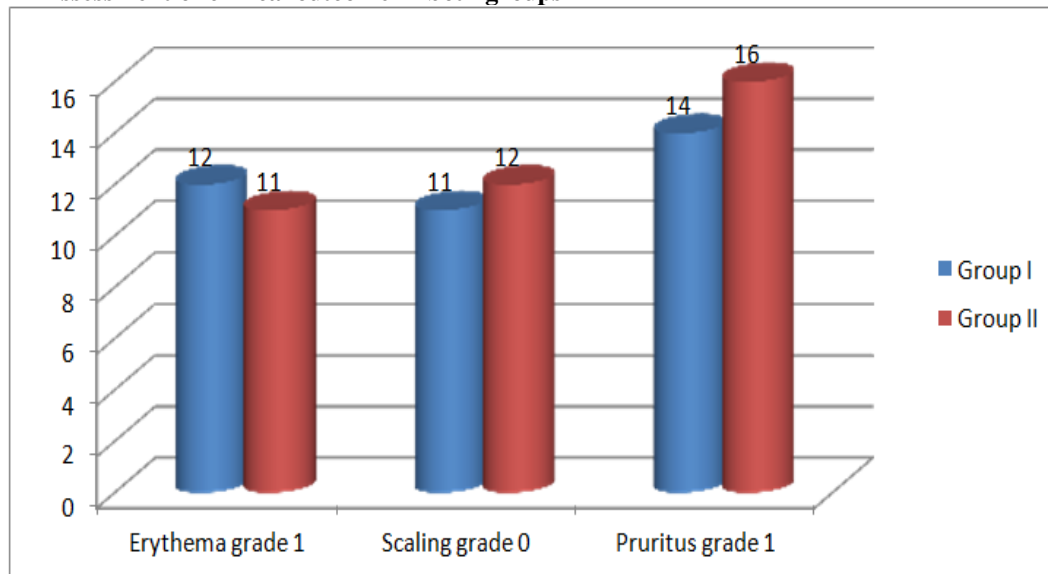
**Graph I Assessment of type of lesions in both groups**



**Table III Assessment of clinical outcome in both groups**

Outcome	Group I	Group II	P value
Erythema grade 1	12	11	0.90
Scaling grade 0	11	12	0.94
Pruritus grade 1	14	16	0.91

Table III, graph I shows that erythema grade 1 was seen in 12 in group I and 11 in group II, scaling grade 0 was seen in 11 in group I and 12 in group II, pruritus grade 1 in 14 in group I and 16 in group II. The difference was non- significant ( $P > 0.05$ ).

**Graph II Assessment of clinical outcome in both groups**

## DISCUSSION

The two varieties of tinea most commonly encountered are tinea corporis affecting trunk and limbs and tinea cruris which affects the inguinal region. Tinea corporis presents as radially advancing, flat, scaly, pruritic macules with a raised border and a characteristic central clearing which earns the sobriquet “ringworm” for these lesions. The latter begins in the inguinal folds and presents usually as bilateral, scaly, dull red, pruritic plaques whose leading edge advances in a sharply demarcated, raised, scaly border.<sup>6</sup> Terbinafine is well absorbed and highly lipophilic and keratophilic, and is distributed throughout adipose tissue, dermis, epidermis, and nails where it persists for weeks. It is delivered to the stratum corneum via the sebum and, to a lesser extent, through incorporation into the basal keratinocytes and diffusion through the dermis- epidermis. Terbinafine is not found in eccrine sweat. Terbinafine is metabolized in the liver.<sup>7</sup>

Sertaconazole is an antifungal agent useful in dermatophytosis such as tinea corporis, tinea cruris, tinea manuum, tinea barbae and tinea pedis, cutaneous candidiasis, pityriasis versicolor and seborrhoeic dermatitis of the scalp.<sup>8</sup> Sertaconazole has broad-spectrum antifungal activity against Trichophyton, Epidermophyton and Microsporum genera, and yeasts of the genera Candida and Cryptococcus and also it is effective against opportunistic infection.<sup>9</sup> The present study compared topical Sertaconazole and topical terbinafine in management of dermatophytoses. In present study, there were 26 males and 20 females in group I patients and 24 males and 22 females in group II.

Chatterjee et al<sup>10</sup> conducted a study in which 88 patients on sertaconazole and 91 on terbinafine were analyzed. At 2 weeks, the clinical cure rates were comparable at 77.27% for sertaconazole and 73.63% for terbinafine. Fourteen patients in either group

improved and on further treatment showed complete healing by another 2 weeks. The final cure rate at 4 weeks was also comparable at 93.18% and 89.01%, respectively. At 2 weeks, 6 (6.82%) sertaconazole and 10 (10.99%) terbinafine recipients were considered as “clinical failure.” Tolerability of both preparations was excellent. We found that Tinea corporis was seen in 24 in group I and 18 in group II and Tinea cruris 22 in group I and 28 in group II. Erythema grade 1 was seen in 12 in group I and 11 in group II, scaling grade 0 was seen in 11 in group I and 12 in group II, pruritus grade 1 in 14 in group I and 16 in group II. Bonifaz et al<sup>11</sup> in their comparative study between terbinafine 1% gel vs ketocanazole 2% cream in tinea cruris and corporis used terbinafine 1% gel once daily for 1 week and observed a clinical and mycological overall evaluation in 72% of patients receiving terbinafine emulsion gel. In our study, we used terbinafine 1% cream twice daily for 3 weeks and attained complete cure rates of 80% and 100% at the end of 2 and 3 weeks, respectively. Millikan<sup>12</sup> in his study on efficacy and tolerability of terbinafine in the treatment of tinea cruris used terbinafine 1% cream twice daily for 2 weeks and observed that therapy was effective in 67% of terbinafine treated patients as compared to 11% in the placebo group.

The limitation of the study is small sample size.

## CONCLUSION

Authors found that both sertaconazole and terbinafine were efficacious in management of dermatophytes.

## REFERENCES

- Jain A, Jain S, Rawat S. Emerging fungal infections among children: A review on its clinical manifestations, diagnosis, and prevention. *J Pharm Bioallied Sci.* 2010;2:314–20.
- Alomar C, Bassas S, Casas M. Multi-centre double-blind trial on the efficacy and safety of Sertaconazole 2% cream in comparison with Miconazole 2% cream on

- patients suffering from cutaneous mycoses. *Arzneimittelforschung*. 1992;42(5A):767-73.
3. Borelli C, Klovekör G, Ernst TM, Bodeker RH, Korting HC, et al. Comparative study of 2% sertaconazole solution and cream formulations in patients with *Tinea corporis*, *Tinea pedis interdigitalis*, or a corresponding candidiasis. *Am J Clin Dermatol*. 2007;8(6):371-78.
  4. Croxtall DJ, Plosker LG. Sertaconazole- A review of its use in the management of superficial mycoses in dermatology and gynaecology. *Drugs*. 2009;69(3):339-59.
  5. Kyle AA, Dahl MV. Topical therapy for fungal infections. *Am J Clin Dermatol*. 2004;5(6):443-51.
  6. Martín-Mazuelos E, Aller AI, Morilla D. Antifungal activity of Sertaconazole in-vitro against clinical isolates of *Candida* spp. *Chemotherapy*. 1996;42(2):112-17. Hay RJ, Ashbee HR. Mycology. In: Rook's textbook of dermatology. Burns T, Breathnach S, Cox N, Griffiths Ceditors. 8th ed. Edinburgh: Wiley Blackwell. 2010;2:36.1-36.93.
  7. Esso DV, Fajo G, Losada I, Vilallonga M, Casanovas JM, Clanxet J, et al. Sertaconazole in the treatment of pediatric patients with cutaneous dermatophyte infections. *Clin Therap* 1995;17:264-9.
  8. McClellan KJ, Wiseman LR, Markham A. Terbinafine. An update of its use in superficial mycoses. *Drugs*. 1999;58:179-202.
  9. Chatterjee D, Ghosh SK, Sen S, Sarkar S, Hazra A, De R. Efficacy and tolerability of topical sertaconazole versus topical terbinafine in localized dermatophytosis: A randomized, observer-blind, parallel group study. *Indian journal of pharmacology*. 2016;48(6):659.
  10. Bonifaz A, Saúl A. Comparative study between terbinafine 1% emulsion-gel versus ketoconazole 2% cream in *tinea cruris* and *tinea corporis*. *Eur J Dermatol* 2000;10:107-9.
  11. Millikan LE. Efficacy and tolerability of topical terbinafine in the treatment of *tinea cruris*. *J Am Acad Dermatol* 1990;23:795-9.