

ORIGINAL RESEARCH

A prospective study of clinico-pathological study of solitary thyroid nodule in a tertiary care centre

¹Linganagouda S Patil, ²Anantharaju GS, ³Ajeet Bhimashankar Revatagaon, ⁴Jagadeesh S Nemagoudra

¹Professor and HOD, Department of General Surgery, SS Institute of Medical Sciences and Research Centre, Davangere, Karnataka, India

²Professor, Department of General Surgery, SS Institute of Medical Sciences and Research Centre, Davangere, Karnataka, India

³Senior Resident, Department of General Surgery, SS Institute of Medical Sciences and Research Centre, Davangere, Karnataka, India

⁴Junior resident, Department of General Surgery, SS Institute of Medical Sciences and Research Centre, Davangere, Karnataka, India

Corresponding Author

Jagadeesh S Nemagoudra

Junior Resident, Department of General Surgery, SS Institute of Medical Sciences and Research Centre, Davangere, Karnataka, India

Received: 02Jan, 2024

Accepted: 25Feb, 2024

ABSTRACT

Background: Solitary thyroid nodules are a common clinical condition, particularly among women, and pose a significant risk due to the potential for malignancy. Accurate diagnosis and management are crucial in reducing the morbidity associated with thyroid disorders. **Objective:** The study aimed to evaluate the incidence, clinical presentation, and histopathological correlation of solitary thyroid nodules in patients treated at a tertiary care center. **Methods:** This prospective study was conducted at the SS Institute of Medical Sciences and Research Centre, Davangere, India. Fifty patients with clinically diagnosed solitary thyroid nodules who underwent surgery were included. Clinical examination, fine needle aspiration cytology (FNAC), and histopathological evaluation were performed to determine the nature of the nodules. **Results:** The study population consisted of 84% females and 16% males, with a female-to-male ratio of 5.25:1. The majority of patients were in the 31-40 age group. FNAC revealed that 60% of the nodules were colloid nodular goitre, followed by 10% follicular neoplasm. Histopathological examination confirmed that 88% of the nodules were benign and 12% were malignant. The most common benign diagnosis was colloid nodular goitre (56%), while the most common malignancy was follicular carcinoma (6%). **Conclusion:** Solitary thyroid nodules are more frequent in females, with a higher risk of malignancy observed in males. FNAC is a valuable tool for preoperative assessment, but histopathological analysis remains essential for definitive diagnosis. Early diagnosis and appropriate management are critical in preventing the progression of malignant nodules.

Key words: Thyroid nodule, Clinico-pathological Study, Thyroid Malignancy

This is an open access journal, and articles are distributed under the terms of the Creative Commons Attribution-Non Commercial-Share Alike 4.0 License, which allows others to remix, tweak, and build upon the work non-commercially, as long as appropriate credit is given and the new creations are licensed under the identical terms.

INTRODUCTION

The thyroid gland, the largest and most accessible endocrine gland in the body, is normally not palpable. Recognized early in the study of endocrine glands, it is located in the lower front and sides of the neck^[1]. Its primary functions include regulating the basal metabolic rate and promoting both somatic and psychic growth. A solitary thyroid nodule refers to a single palpable nodule within an otherwise normal thyroid gland^[2]. Approximately 70% of these nodules are clinically isolated, while 30% are dominant^[3]. The

primary concern with a solitary thyroid nodule is its potential malignancy, underscoring the need for accurate diagnosis and appropriate treatment^[4].

Solitary palpable nodules are four times more common in women than in men. Typically, nodules larger than 1 cm in diameter are detectable by touch. Ultrasound studies have shown that 50-70% of individuals without a history of thyroid disease may have incidental thyroid nodules that are not palpable^[5]. Fine needle aspiration cytology (FNAC) is a highly sensitive diagnostic method that plays a

crucial role in determining whether surgical intervention is needed. It is a simple, quick procedure with high patient compliance and is currently the first-line screening tool for thyroid disorders^[4, 6].

Common symptoms include swelling in the neck, difficulty swallowing (dysphagia), difficulty breathing (dyspnoea), and hoarseness of voice. Characteristics suggestive of malignancy include a firm to hard, painful, and rapidly growing nodule that is fixed to surrounding structures and associated with lymphadenopathy^[7].

Objective

The aim of this study was to study the incidence and other clinical parameters of solitary thyroid nodules and to correlate between clinical diagnosis and histopathological examination of solitary nodule thyroid.

Materials and Methods

A prospective study had been carried out in the Department of General Surgery, SSIMS & RC, Davangere India. Patients with solitary thyroid swelling and underwent some forms of surgery were selected and included in this study.

Inclusion criteria

- Patients with solitary thyroid swelling.
- Patients between 20 to 80 years of age.
- Both male and female patients.

Exclusion criteria

- Patients with thyroid swellings other than solitary nodules clinically and surgically proved (multinodular goitre).
- Thyroiditis cases.
- Patients unfit for surgery under anaesthesia.
- Patients unwilling for the interventions.

Patients included in the study were asked about history related to the thyroid swelling and relevant questions to the etiological cause. Present, past and family history of thyroid and other relevant histories were asked. Detailed General physical, clinical examination and thyroid swelling examination were done. The patients were investigated. Apart from routine investigations, all patients had a thyroid profile, fine needle aspiration cytology (FNAC), X-ray of the neck-anteroposterior and lateral views, chest X-ray and indirect laryngoscopy were done. In patients presenting with hypo or hyperthyroidism, medical therapy was planned to attain euthyroid state. For inclusion in this study, a solitary thyroid nodule is

defined as a single swelling involving either lobe or isthmus of the thyroid gland. Patients underwent surgery, and the histopathological reports were evaluated and correlated with clinical diagnosis by standard statistical methods.

Results

In this study age of patient ranged from 22 years-76 years. But most of the patient were aged between 3rd and 4th decade. Out of 50 cases 42 patients (84%) were female and 8 patients (16%) were male. Female to male ratio 5.25:1. Minimum age of the subject was 22 years and maximum age was 76 years (Table 1). (Figure 2) Location of swelling right lobe 70% Left lobe 26% and isthmus 4%. All the patient present with visible or palpable swelling in front of neck (100%). Among them 8% patients present with cervical lymphadenopathy, 12% patient present with pain, and 2% presented with hoarseness voice and dysphagia (Table 2). Most of the nodule 80% were firm in consistency, 12% were hard & 8% were cystic (Table 3). FNAC is the most important step in the workup of thyroid nodule and it was done in all patient 100%. It showed 30 patients (60%) were colloid nodular goitre followed by follicular neoplasm 5 patient (10%), cystic degeneration 5 patient (10%) and thyroiditis 4 patient (8%). Final diagnosis was confirmed by histopathological report. Most of the patient were diagnosed colloid nodular goitre 28 (56%), then follicular adenoma 8 (16%). In this study 88% thyroid nodule were benign and 12% were malignant (Table 4).

Table 1: Distribution of patient according to age and sex

Age(Years)	Male	Female	Total	Percentage
21-30	2	13	15	30%
31- 40	2	16	18	36%
41-50	2	5	7	14%
51- 60	2	8	10	20%
Total	8	42	50	100%

Table 2: Presenting Symptoms (n=50)

Symptom	No. of patient	Percentage
Swelling in front of neck	50	100%
Pain	6	12%
Cervical lymphadenopathy	4	8%
Hoarseness of voice	1	2%
Dysphagia	2	4%
Dyspnoea	1	2%

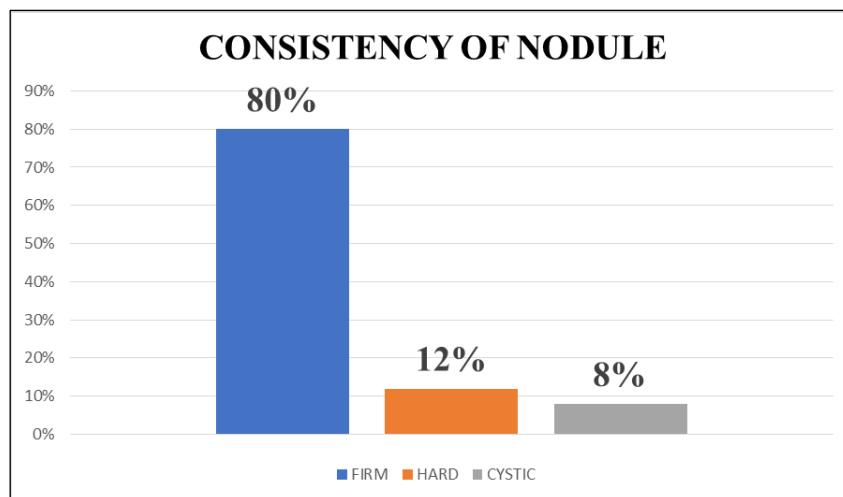


Fig 1: Consistency of nodule (n=50)

Table 3: FNAC findings (n=50)

Diagnosis	No. of patient	Percentage
Colloid nodular goitre	30	60%
Follicular neoplasm	5	10%
Thyroiditis	4	8%
Cystic Degeneration	5	10%
Papillary carcinoma	2	4%
Follicular adenoma	3	6%
Anaplastic carcinoma	1	2%

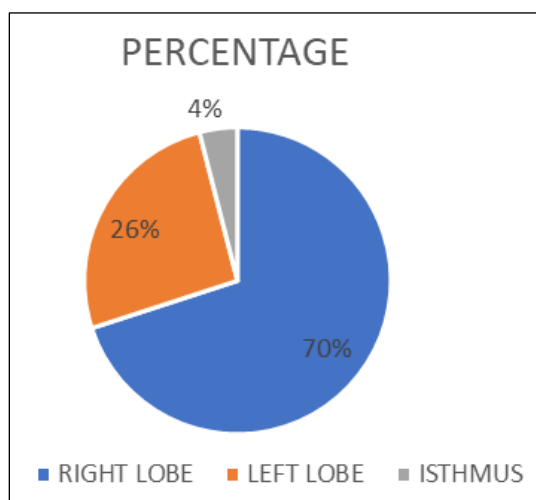


Figure 2: Location of swelling (n=50)

Table 5: Histopathological report of this study

Diagnosis	No. of patients	Percentage
Nodular colloid goitre	28	56%
Multinodular goitre	2	4%
Follicular adenoma	8	16%
Thyroiditis	6	12%
Papillary carcinoma	2	4%
Follicular carcinoma	3	6%
Anaplastic carcinoma	1	2%
Total	50	100%

Discussion

Thyroid swelling is a prevalent clinical issue in our country^[8]. Thyroid nodules are 3 to 4 times more common in women than in men. The majority of patients are in the 31 to 40-year age group (36%), followed by the 21 to 30-year age group (30%). These results align with similar studies^[9]. In this study of 50 patients, there were 8 males (16%) and 42 females (84%), resulting in a male-to-female ratio of 1:5.25, which is similar to the ratio reported by Rahman MJ^[10]. Female predominance is consistent across all studies, including this one.

Solitary thyroid nodules are not a single clinical entity, making it challenging to determine their nature based solely on clinical examination. However, symptoms such as hoarseness of voice, a hard irregular nodule, palpable cervical lymph nodes, extreme age, and male sex are generally indicative of a higher risk for malignancy in solitary thyroid nodules^[11, 12].

The most common symptom reported among all patients was swelling in the front of the neck (100%), followed by cervical lymphadenopathy and pain (8%). These findings are consistent with observations by S M NazmulHuqueet al.^[13-15]. Other symptoms observed were dysphagia (4%), hoarseness of voice (4%), and dyspnoea (2%), which aligns with findings by Abdullah Al Mamunet al.^[16].

In our study, 40 nodules were firm, 6 were hard, and 4 were cystic. Of the 6 hard nodules, 4 were diagnosed as malignant and 2 as multinodular goitre. While hardness alone is not definitive, it is an important indicator of potential malignancy^[17, 18]. All patients in this study had thyroid hormone profiles within normal limits. Ultrasonography is essential for assessing the physical characteristics of nodules and for identifying clinically undetectable nodules in dominant nodular goitre.

Fine needle aspiration cytology (FNAC) is a highly specific, sensitive, and minimally invasive diagnostic tool. In our study, FNAC of solitary thyroid nodules revealed 60% colloid nodules, 10% colloid

degeneration, and 10% follicular neoplasms. These results are consistent with those reported by Abhijit S. Ruyteet *et al.* [19]. FNAC results were corroborated by postoperative histopathological reports. The final diagnoses in this study included colloid nodular goitre (28 cases, 56%), follicular adenoma (8 cases, 16%), thyroiditis (6 cases, 12%), papillary carcinoma (2 cases, 4%), follicular carcinoma (3 cases, 6%), and anaplastic carcinoma (1 case, 2%). These findings are similar to those reported by AbulHasan *et al.* [20, 21]. This study, conducted over a limited period and with a small patient sample, may not fully represent broader trends. Nevertheless, it provides valuable insights from a tertiary hospital setting in our country.

Conclusion

Solitary thyroid nodules are more common in females but pose a greater concern in males due to a higher incidence of malignancy. FNAC is an invaluable tool for the preoperative assessment of solitary thyroid nodules, though malignancies can still be unexpected in postoperative histopathological examinations. A comprehensive evaluation of thyroid nodules should include patient history, clinical examination, ultrasound findings, and FNAC results. Definitive diagnosis requires surgical excision and histopathological analysis. Given that a significant proportion of solitary cold nodules may be malignant, early diagnosis and appropriate treatment are crucial.

Acknowledgment

Thanks to all patients and doctors of General Surgery & Pathology Department of SSIMS & RC for their sincere cooperation acknowledged by the authors.

References

- McGlashan JA. The thyroid gland: anatomy and physiology. In: Gleeson M, editor. *Scott-Brown's Otorhinolaryngology, Head and Neck Surgery*. 7th ed. London: Hodder Arnold; c2008. p. 314.
- Krukowski ZH. The thyroid gland and the thyroglossal cyst. In: Russell RCG, Norman, editors. *Bailey and Love's Short Practice of Surgery*. 23rd ed. London: Arnold; c2000. p. 712.
- Rao BH, Chakravarthy KS. Study of incidence between benign and malignant tumours of solitary thyroid nodule. *Int. J. Res. Med. Sci.* 2016 Dec;4(12):5288-5292.
- Haque SMN, Ali MI, Huq MM, Rumi SKN, Sattar MA, Khan AFM. Histopathological pattern of malignancy in solitary thyroid nodule. *Bangladesh J Otorhinolaryngol.* 2012;18(1):5-10.
- Mamun AA, Alam Z, Islam M, Mahmud M, Rahman M, Aich ML. Study of pathological variation of solitary thyroid nodule. *Bangladesh J Otorhinolaryngol.* 2018;24(2):105-114.
- Karim MI, Nachev R, Fuklev N, Nargis N. A study on evaluation of solitary nodular lesions by FNAC and histopathological correlation. *Bangladesh J Med. Sci.* 2019;18(4):789-795.
- Edwin IA. Clinicopathological study of solitary nodule of thyroid: A prospective study. *Int. J. Sci. Stud.* 2020;8(9):77-80.
- Haque GH, Hossain MJ, Haque S, Rahman MA. *Medicine today.* 2019;31(2):85-87.
- Rayte AS. Clinicopathological study of solitary thyroid nodule. *MedPulse Int. J Surg.* 2018;6(3):91-93.
- Rahman MJ, Mustafa MG. Comparative study of cancer developing in solitary thyroid nodule and multinodular goiter. *Bangladesh J Otorhinolaryngol.* 2000;6(11):6-12.
- Mamun AA, Alam Z, Islam M, Mahmud M, Rahman M, Aich ML. Study of pathological variation of solitary thyroid nodule. *Bangladesh J Otorhinolaryngol.* 2018;24(2):105-114.
- Ashraf SA, Matin ASM. A review of thyroid disease in Bangladesh. *J BCPS.* 1996;2(1):6-10.
- Edwin IA. Clinicopathological study of solitary nodule of thyroid: A prospective study. *Int. J. Sci. Stud.* 2020;8(9):77-80.
- Sattar MA, Alam MR, Haider A. Clinicopathological study of solitary cold thyroid nodule. *Bangladesh J Otorhinolaryngol.* 2003;9(1):24-27.
- Huque SM, Ali MI. Histopathological pattern of malignancy in solitary thyroid nodule. *Bangladesh J Otorhinolaryngol.* 2012;18(1):5-10.
- Alauddin M, Joarder MAH. Management of thyroid carcinoma. *Bangladesh J Otorhinolaryngol.* 2003;9:33-37.
- Haque SMN, Ali MI, Huq MM, Rumi SKN, Sattar MA, Khan AFM. Histopathological pattern of malignancy in solitary thyroid nodule. *Bangladesh J Otorhinolaryngol.* 2012;18(1):5-10.
- Vender JB, Gaston EA, Dawber TR. The significance of nontoxic thyroid nodules. *Ann Intern Med.* 1968;69:537-540.
- Rayte AS. Clinicopathological study of solitary thyroid nodule. *MedPulse Int. J Surg.* 2018;6(3):91-93.
- Hossain MA, Sarker MZ, Dutta UK, Karim MA, Alam MZ. Frequency of malignancy in solitary thyroid nodule and multinodular goitre. *Bangladesh J Otorhinolaryngol.* 2014;20(2):55-65.
- Mackenzie EJ, Mortimer RH. Thyroid nodule and thyroid cancer. *Med J Aust.* 2004;180(5):242-247.