

**ORIGINAL RESEARCH****Evaluation of variations of sciatic nerve**<sup>1</sup>Dr. Babita Priti, <sup>2</sup>Dr. Manish Kumar, <sup>3</sup>Dr. Amresh Kumar<sup>1</sup>Tutor, Department of Anatomy, GMCH Purnea, Bihar, India<sup>2</sup>Tutor, Department of Anatomy, JNKTMCH Madhepura, Bihar, India<sup>3</sup>Medical Officer, Department of Anatomy, Village & Post –Sori District –Aurangabad P. S - Mali Bihar, India**Corresponding Author**

Dr. Manish Kumar

Tutor, Department of Anatomy, JNKTMCH Madhepura, Bihar, India

Received Date: 20 May, 2024

Acceptance Date: 27 June, 2024

**ABSTRACT****Background:**The sciatic nerve, which originates from the lumbosacral region, is the biggest nerve in the human body. It is composed of five nerve roots (L4-S3). The present study was conducted to assess variations of the sciatic nerve.**Materials & Methods:**60 formalin fixed cadavers were selected and The Beaton and Anson classification system was used to classify anatomic variations. Divisions of sciatic nerve division was also recorded.**Results:** Type 1 was seen in 47, type 2 in 3, type 3 in 4, type 4 in 1 and type 5 in 3 and type 6 in 2 cases. The difference was significant ( $P < 0.05$ ).The level of division of sciatic nerve was at D1 in 20, at D2 in 4, at D3 in 3, at D4 in 32 and at D5 in 1 case. The difference was significant ( $P < 0.05$ ).**Conclusion:** The location, branching, and distribution of the sciatic nerve have clinical significance. The sciatic nerve's long route makes it vulnerable to injury, which is why it is commonly utilized in common medical operations like anesthesia, rehabilitation, orthopaedics, and neurology.**Key words:**Sciatic nerve, anesthesia, rehabilitation

This is an open access journal, and articles are distributed under the terms of the Creative Commons Attribution- Non Commercial-Share Alike 4.0 License, which allows others to remix, tweak, and build upon the work non-commercially, as long as appropriate credit is given and the new creations are licensed under the identical terms.

**INTRODUCTION**

The sciatic nerve, which originates from the lumbosacral region, is the biggest nerve in the human body. It is composed of five nerve roots (L4-S3).<sup>1</sup>The two nerve components it carries are the common-peroneal component (L4, 5, S1, and S2) and the tibial component (L4, 5, S1, S2, and S3). According to normal anatomy, this nerve passes inferior to the piriformis muscle when it enters the gluteal region from the pelvis through the larger sciatic foramen.<sup>2</sup>

The degree to which the sciatic nerve bifurcates into the tibial nerve and the common fibular nerve from the sacral plexus to the popliteal fossa has been observed by a number of writers and researchers.<sup>3</sup> Throughout a person's life, compression of the sciatic nerve caused by unilateral or bilateral congenital higher divisions of the sciatic nerve can result in a variety of clinical conditions, such as sciatica, piriformis syndrome, sleeping foot, failure or sparing of the sciatic nerve block during lower limb surgeries, etc.<sup>4,5</sup> The pain that results from a compression or irritation of the sciatic nerve is known as sciatica. Sciatica is characterized by pain, tingling, numbness, and weakness. One of the causes of sciatica is piriformis syndrome, which results from the piriformis muscle's aberrant structure and position

compressing the sciatic nerve.<sup>6</sup>The present study was conducted to assess variations of the sciatic nerve.

**MATERIALS & METHODS**

The present study was conducted in Department of Anatomy of GMCH Purnea, Bihar, India from July 2023 to December 2023. The present study consisted of 60 formalin fixed cadavers. Ethical clearance was obtained before starting the study. The Beaton and Anson classification system was used to classify anatomic variations. Type-1 represents an undivided nerve below an undivided muscle; Type-2 represents nerve divisions between and below an undivided muscle; Type-3 represents divisions above and below an undivided muscle; Type-4 represents an undivided nerve between heads; Type-5 represents divisions between and above heads; and Type-6 represents an undivided nerve above an undivided muscle. Divisions of sciatic nerve division was marked as D1- At gluteal region, D2- At upper part of thigh, D3- At middle part of thigh, D4 - Lower part of thigh near superior angle of popliteal fossa, D5- Lowermost, in the popliteal fossa posterior to knee joint. Data thus obtained were subjected to statistical analysis. P value  $< 0.05$  was considered significant.

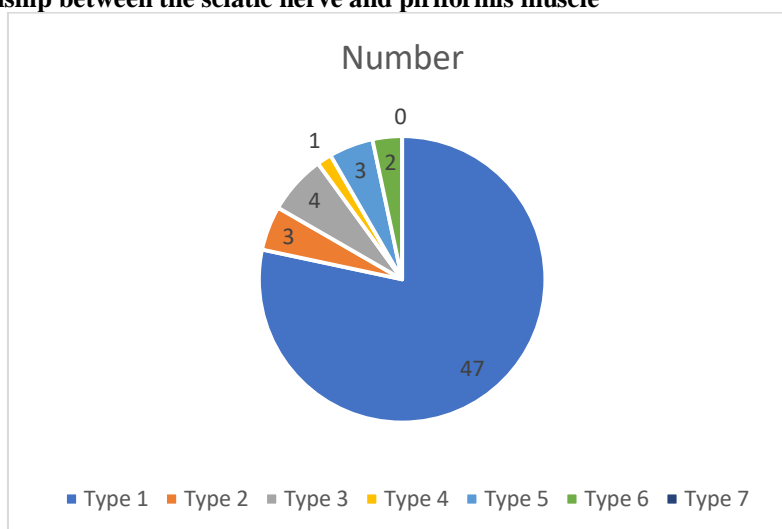
## RESULTS

**Table: I Relationship between the sciatic nerve and piriformis muscle**

Type	Number	P value
Type 1	47	0.01
Type 2	3	
Type 3	4	
Type 4	1	
Type 5	3	
Type 6	2	
Type 7	0	

Table I, graph I shows that type 1 was seen in 47, type 2 in 3, type 3 in 4, type 4 in 1 and type 5 in 3 and type 6 in 2 cases. The difference was significant ( $P < 0.05$ ).

**Graph I: Relationship between the sciatic nerve and piriformis muscle**



**Table: II Level of divisions of sciatic nerve**

Level	Number	P value
D1	20	0.01
D2	4	
D3	3	
D4	32	
D5	1	

Table II shows that level of division of sciatic nerve was at D1 in 20, at D2 in 4, at D3 in 3, at D4 in 32 and at D5 in 1 case. The difference was significant ( $P < 0.05$ ).

## DISCUSSION

The sciatic nerve is the thickest nerve in the body, measuring 2 cm at its origin. The larger sciatic foramen beneath the piriformis is where the sciatic nerve exits the pelvis and enters the gluteal area.<sup>7,8</sup> Subsequently, it traverses the greater trochanter and ischial tuberosity before descending into the thigh's posterior compartment. There, it splits at a different level proximal to the knee into the tibial and common fibular nerves.<sup>9,10</sup> While the common fibular nerve is lateral and consists of dorsal divisions of anterior primary rami of L4, L5, S1, S2, and S3, the tibial nerve is medial and consists of ventral divisions of these anterior primary rami. The sciatic nerve nourishes the leg, thigh, and rear muscular sections.<sup>11,12</sup> The present study was conducted to assess variations of the sciatic nerve. We found that

type 1 was seen in 47, type 2 in 3, type 3 in 4, type 4 in 1 and type 5 in 3 and type 6 in 2 cases. Shewaleet al<sup>13</sup> observed the variations in division of sciatic nerve as compared to known facts. The inferior extremities of 45 cadavers were examined and variations of division of sciatic nerve were noted and classified. The highest incidence of sciatic nerve variation was observed in its termination. In 11.11% of cases the sciatic nerve was found to be divided in the gluteal region. In 11.11% specimens, the common peroneal nerve pierced the piriformis muscle. We observed that level of division of sciatic nerve was at D1 in 20, at D2 in 4, at D3 in 3, at D4 in 32 and at D5 in 1 case. Adibattiet al<sup>14</sup> in their study fifty lower limbs were used for the study. On 25 cadavers (50 lower limbs), they have observed 4 (8 %) lower limbs high division of sciatic nerve. High division of sciatic nerve in the

back of thigh was noted in one specimen (2%), while high division within the pelvis was noted in 3 specimens (6%), while in 46 (92%) it occurred outside the pelvis.

Sinha et al<sup>15</sup> in their study four types of relationship of the sciatic nerve with the piriformis muscle were observed in one hundred gluteal regions of fifty spontaneously aborted, formalin-fixed fetuses, aged 20 to 36 week (24 males and 26 females). In 85% of the gluteal regions, the classic pattern was found, in which the two components of the sciatic nerve fuse with each other proximal to the piriformis, and the fused sciatic nerve emerges at the lower border of the piriformis. In the remaining 15% of the gluteal regions, variations in relationship were found. The most common variation, characterized by the passage of the common peroneal component through the piriformis and the emergence of the tibial part at the lower border of the piriformis, was seen in 9% of the gluteal regions. Common peroneal and tibial components passed above and below the muscle respectively in 3%, and the unsplit sciatic nerve passed through the piriformis in 3% of the gluteal regions. Four types of fusion of the piriformis with the neighbouring muscles were seen: namely, no fusion; fusion with superior gemellus; fusion with gluteus medius, or fusion with gluteus medius and obturatorinternus complex in 28%, 43%, 26% and 3% of the gluteal regions respectively. Anatomical variations of the sciatic nerve in relation to the piriformis muscle should be kept in mind while performing medical or surgical interventions in this region. The limitation of the study is the small sample size.

## CONCLUSION

Authors found that the location, branching, and distribution of the sciatic nerve have clinical significance. The sciatic nerve's long route makes it vulnerable to injury, which is why it is commonly utilized in common medical operations like anesthesia, rehabilitation, orthopaedics, and neurology.

## REFERENCES

- Güvençer M, Iyem C, Akyer P, Tetik S, Naderi S. Variations in the high division of the sciatic nerve and relationship between the sciatic nerve and the piriformis. *Turk Neurosurg.* 2009;19(2):139-44.
- Lewis S, Jurak J, Lee C, Lewis R, Gest T. Anatomical variations of the sciatic nerve, in relation to the piriformis muscle. *Translational Research in Anatomy.* 2016;5:15-9.
- Machado FA, Babinski MA, Brazil FB, Favorito LA, Abidu-Figueiredo M, Costa MG. Anatomical variations between sciatic nerve and piriform muscle during fetal period in human. *Int J Morphol.* 2003;21(1):29-35.
- Ozaki S, Hamabe T, Muro T. Piriformis syndrome resulting from an anomalous relationship between the sciatic nerve and piriformis muscle. *Orthopedics.* 1999;22(8):771-2.
- Kim HJ, Lee SY, Park HJ, Kim KW, Lee YT. Accessory Belly of the Piriformis Muscle as a Cause of Piriformis Syndrome: A Case Report with Magnetic Resonance Imaging and Magnetic Resonance Neurography Imaging Findings. *Investigative Magnetic Resonance Imaging.* 2019;23(2):142-7.
- Anyanwu GE, Udemezue OO, Obikili EN. Dark age of sourcing cadavers in developing countries: A Nigerian survey. *Clin Anat.* 2011;24(7):831-6.
- Gangata H, Ntaba P, Akol P, Louw G. The reliance on unclaimed cadavers for anatomical teaching by medical schools in Africa. *AnatSci Educ.* 2010;3(4):174-83.
- Beaton LE. The sciatic nerve and piriform muscle: their interrelations possible cause of coccygodynia. *J Bone Joint Surg Am.* 1938;20:686-8.
- Berihu BA, Debeb YG. Anatomical variation in bifurcation and trifurcations of sciatic nerve and its clinical implications: in selected university in Ethiopia. *BMC Res Notes.* 2015;8:633.
- Pećina M. Contribution to the etiological explanation of the piriformis syndrome. *ActaAnat (Basel).* 1979;105(2):181-7.
- Pokorny D, Jahoda D, Veigl D, Pinskerova V, Sosna A. Topographic variations of the relationship of the sciatic nerve and the piriformis muscle and its relevance to palsy after total hip arthroplasty. *SurgRadiol Anat.* 2006;28(1):88-91.
- Javia MD, Vikani SK. Cadaveric Study on Variations in the Level of Bifurcation of Sciatic Nerve and its Clinical Implications. *International Journal of Anatomy, Radiology and Surgery.* 2019;8:29-32.
- Shewale AD, Karambelkar RR, Umarji BN. Study of variations in the divisions, course and termination of the sciatic nerve. *J Krishna Inst Med Sci Univ.* 2013 Jan 1;2(1):62-8.
- Adibatti M, Sangeetha V. Study on variant anatomy of sciatic nerve. *Journal of clinical and diagnostic research: JCDR.* 2014 Aug;8(8):AC07.
- Sinha MB, Aggarwal A, Sahni D, Harjeet K, Gupta R, Sinha HP. Morphological variations of sciatic nerve and piriformis muscle in gluteal region during fetal period. *Eur J Anat.* 2014;18(4):261-6.