

**ORIGINAL RESEARCH**

# Comparative prospective analysis of functional outcomes in displaced neck of femur fractures among the elderly: uncemented hemiarthroplasty versus total hip arthroplast

<sup>1</sup>Dr. Anand Shrivastav, <sup>2</sup>Dr. Saurabh Saxena, <sup>3</sup>Dr. Naren Khatri, <sup>4</sup>Dr. Imran Khan

<sup>1</sup>Assistant Professor, Integral Institute of Medical Sciences, Lukhnow, India

<sup>2</sup>Associate Professor, GSUM, Kanpur, India

<sup>3</sup>Consultant, Department of Orthopedics, Sitapur, Hospital, Gujarat, India

<sup>4</sup>Consultant, Down Town Hospital, Guhwati, India

## Corresponding Author

Dr. Anand Shrivastav

Assistant Professor, Integral Institute of Medical Sciences, Lukhnow, India

Received: 07 February, 2025

Accepted: 24 February, 2025

Published: 18 March, 2025

## ABSTRACT

**Background:** Displaced neck of femur fractures inside the aged populace represent a good sized medical project. two primary surgical alternatives—hemiarthroplasty (HA) and overall hip arthroplasty (THA)—are normally employed, each with wonderful benefits and capability complications. even as hemiarthroplasty is technically less difficult and associated with reduced operative time, overall hip arthroplasty offers better lengthy-time period results in selected sufferers but can also deliver a higher risk of dislocation. **Methods:** A potential, observational look at changed into carried out on 30 elderly sufferers ( $\geq 60$  years) with acute, displaced neck of femur fractures ( $< 2$  weeks vintage). patients had been treated either with the aid of uncemented modular bipolar hemiarthroplasty (HRA) or uncemented THA. Operative details, intraoperative blood loss, and postoperative headaches had been documented. purposeful results were evaluated the use of the Harris Hip score (HHS) at everyday periods up to 6 months. Statistical comparisons between businesses have been accomplished the use of appropriate checks ( $p < 0.05$  considered widespread). **Results:** A number of the have a look at members (imply age  $72.7 \pm 7.8$  years), 17 underwent HRA and thirteen underwent THA. imply operative time turned into significantly higher in the THA organization (91.three vs. 59.7 minutes;  $p < 0.001$ ). average blood loss additionally extensively differed (THA: 490 ml vs. HRA: 323.five ml;  $p < 0.001$ ). each companies confirmed favorable functional healing at 6 months, with a majority of patients achieving excellent or right Harris Hip rankings. overall complications have been low, though the THA institution had one case of postoperative dislocation and one mortality, whilst the HRA institution said a single example of superficial strain sore. **Conclusion:** both uncemented hemiarthroplasty and THA offer great functional outcomes in displaced neck of femur fractures within the aged. THA requires longer operative time and is related to better blood loss and a doubtlessly greater threat of headaches, but might also offer advanced mobility in pick out sufferers.

**Keywords:** Displaced femoral neck fracture, Hemiarthroplasty, overall hip arthroplasty, Harris Hip score, elderly orthopaedics

This is an open access journal, and articles are distributed under the terms of the Creative Commons Attribution-Non Commercial-Share Alike 4.0 License, which allows others to remix, tweak, and build upon the work non-commercially, as long as appropriate credit is given and the new creations are licensed under the identical terms.

## INTRODUCTION

Neck of femur fractures in the aged remain a prime fitness subject because of increasing lifestyles expectancy and the associated decline in bone first-rate [1]. these fractures usually occur due to minimal trauma, which include a simple slip or a low-electricity fall, which underscores the fragility of osteoporotic bone in advanced age organizations [2]. Clinically, displaced femoral neck fractures are

notorious for their excessive morbidity and mortality prices if not controlled accurately and in a timely manner. Surgical intervention is widely recognized as the same old of care, aiming to lessen postoperative pain, restore mobility, and limit complications together with mattress sores and pulmonary problems [3,4].

Hemiarthroplasty (HA) and general hip arthroplasty (THA) are not unusual surgical processes hired for

displaced femur neck fractures inside the elderly [5]. Hemiarthroplasty, involving replacement of the femoral head with a bipolar or unipolar prosthesis, commonly calls for shorter operative time and is regularly related to reduced intraoperative blood loss. it's far specially favored in frail people who won't tolerate prolonged anesthesia or who've restricted life expectancy [6]. on the other hand, general hip arthroplasty replaces both the femoral head and the acetabular floor. it is able to provide enhanced practical effects, higher variety of movement, and stepped forward patient delight—mainly for the extra energetic elderly populace. but, THA also incorporates a potentially better threat of dislocation and longer operative instances, and may be technically more demanding, thus increasing the chance of higher intraoperative blood loss [7,8].

every other vital factor is the useful final results evaluation, for which the Harris Hip rating (HHS) is widely used in clinical and studies settings. The HHS offers a standardized degree of postoperative pain control, gait, range of movement, and typical characteristic. through comparing HHS results in patients undergoing HA versus THA, surgeons can better recognize the efficacy, affected person delight, and complications of each approach [3].

This potential observational look at objectives to systematically compare and compare the consequences of uncemented modular bipolar hemiarthroplasty (HRA) and uncemented THA in aged sufferers with displaced femoral neck fractures. primary objectives consist of the assessment of useful recovery based at the HHS and the prevalence of key postoperative complications together with dislocation, infection, and mortality. We hypothesize that whilst both surgical strategies will yield favorable practical outcomes, THA may be associated with a higher surgical burden but provide capability lengthy-time period advantages in mobility for selected patients. The findings of this have a look at will guide orthopedic surgeons in making evidence-based totally decisions tailor-made to individual patient traits, comorbidities, and long-term practical expectancies [4–8].

## MATERIALS AND METHODS

### Examine Design And Putting

This changed into a prospective, observational take a look at involving aged sufferers ( $\geq 60$  years) offering with acute, displaced fracture of the femoral neck. sufferers have been evaluated in the Outpatient and Emergency Departments of Orthopedics at Downtown hospital, Guwahati. The observe duration turned into 12 months (from may also 1, 2017, to April 30, 2018). Thirty instances meeting the eligibility standards have been protected.

### Inclusion and Exclusion criteria

#### Inclusion Criteria

1. Age  $\geq 60$  years, both intercourse.

2. Acute ( $\leq 2$  weeks old) displaced femur neck fractures.
3. sufferers providing knowledgeable consent.
4. able vascular and neurological fame inside the affected limb.
5. Contralateral decrease limb sufficiently practical for rehabilitation.

#### Exclusion Criteria

1. Refusal to offer consent.
2. Undisplaced femur neck fractures.
3. patients with severe cognitive disorder.
4. injuries  $> 2$  weeks old.
5. Pathological fractures or advanced pre-current arthritis.
6. sufferers unable to take part in postoperative rehabilitation.
7. Contraindications to surgical procedure or anesthesia.
8. associated predominant ipsilateral or contralateral limb injuries affecting treatment or rehabilitation.

#### Pattern Size And Technique

At the least 30 sufferers had been recruited by using non-random sampling. sufferers pleasurable the inclusion criteria had been very well informed about each strategies (HRA vs. THA) and allowed to choose their favored surgical procedure. The sample length changed into chosen in view of the feasibility in the stipulated take a look at duration.

#### Preoperative Workup

All admitted patients acquired symptomatic treatment, including dollar's traction to the affected limb. an in depth medical records (such as age, sex, socioeconomic fame, mode of damage, previous ailments) changed into recorded. popular radiographs—anteroposterior view of the pelvis with 15° inner rotation and lateral view of the affected limb—had been used for prognosis and category (lawn's category). informed consent was obtained after explaining the character of the fracture, surgical risks, and observe parameters.

#### Surgical Methods

Each uncemented modular bipolar hemiarthroplasty (HRA) and uncemented overall hip arthroplasty (THA) observed the same old posterior (Moore's) approach. All surgical procedures had been done by using the identical senior consultant under blended spinal-epidural anesthesia.

#### Implants

- For HRA: Uncemented modular bipolar prosthesis (Accolade stem, sizes 0–5, with a modular bipolar cup ranging from 38–fifty six mm).
- For THA: Uncemented Accolade femoral stem and Trident acetabular shell, with a move-related

polyethylene liner. Femoral heads have been Vitallium alloy (sizes 22, 26, or 28 mm).

### Operative Approach

1. Posterior method: With the patient in lateral decubitus, a curved incision targeted over the posterior factor of the extra trochanter became made. the fast external rotators had been tagged and detached to reveal the pill.
2. Femoral coaching: The femoral neck become cut the use of a neck-cutting guide. The canal changed into sequentially reamed and broached to deal with the trial prosthesis. stability and period were assessed before very last implantation of the definitive stem and head.
3. Acetabular practise (THA): The acetabulum was reamedhemispherically and trial cups examined for congruity. The definitive acetabular shell turned into impacted and secured with or without screws, observed via a polyethylene liner insertion.
4. Closure: The pill changed into repaired. The external rotators have been reattached, and the wound changed into closed over a suction drain.

### Antibiotic and DVT Prophylaxis

A wellknown antibiotic regimen (preoperative intravenous cefuroxime 1.5 g and amikacin 500 mg) changed into continued for 48 hours postoperatively, accompanied via oral antibiotics as needed. Deep vein thrombosis prophylaxis (fondaparinux 2.5 mg SC) turned into given for five days postoperatively.

### Postoperative Control And Follow-Up

- Drain removal: usually at 48 hours if drainage become minimum.
- Physiotherapy: Early mobilization with a walker, quadriceps strengthening, and avoidance of crossing legs or squatting.
- observe-Up Visits: conducted at 6 weeks, 12 weeks, and six months. Harris Hip rating (HHS) changed into assessed at each observe-as much as screen pain, feature, variety of motion, and gait. Radiographs were checked for implant position, osteolysis, and other complications.

### Outcome Measures

Number one outcomes protected the Harris Hip rating and occurrence of headaches (contamination, dislocation, mortality). Secondary measures have been operative time, intraoperative blood loss, and period to full weight-bearing.

## REPRESENTATIVE TABLES

**Table 1. Age Distribution of the Study Population (n=32)**

Age (years)	n	Percentage (%)
60–65	8	25.0
66–70	7	21.9
71–75	5	15.6
76–80	7	21.9

## RESULTS

### Overview of Findings

A total of 32 patients met inclusion criteria; 2 dropped out or were excluded, leading to 30 evaluable participants for final analysis. Ultimately, 17 underwent uncemented modular bipolar HRA, and 13 received uncemented THA. The mean age was  $72.7 \pm 7.8$  years (range: 60–86), and the majority of fractures resulted from low-energy trauma (simple falls). There was a female predominance (19 females vs. 13 males).

Below are summarized key results in narrative form, followed by representative tables and figures.

#### 1. Demographics and Comorbidities

- Mean age: 72.7 years
- Female-to-male ratio: 19:13
- Left hip was more frequently involved (56.25%).
- Hypertension (28%), diabetes mellitus (34.3%), and anemia (31.2%) were the most common comorbidities.

#### 2. Operative Time and Blood Loss

- Mean operative time was significantly longer in THA (91.3 minutes) vs. HRA (59.7 minutes;  $p < 0.001$ ).
- Mean intraoperative blood loss was also significantly higher in THA (490 ml) compared to HRA (323.5 ml;  $p < 0.001$ ).

#### 3. Complications

- One case of postoperative dislocation and one mortality occurred in the THA group.
- The HRA group had one patient with a superficial pressure sore, which resolved with conservative measures.
- No deep infections or periprosthetic fractures were noted in either group.

#### 4. Functional Outcomes

- At 6 months, Harris Hip Score outcomes were largely excellent or good in both groups.
- In HRA, 70.6% had excellent results and 23.5% good results.
- In THA, 78.6% had excellent results and 14.3% good results.
- Range of motion parameters (flexion, abduction, rotation) were comparable, with no statistically significant differences except a marginally higher external rotation range in the THA group.

#### 5. Time to Full Weight-Bearing

- THA group had a marginally earlier full weight-bearing time ( $2.21 \pm 0.58$  weeks) compared to HRA ( $2.88 \pm 0.93$  weeks), although this difference was not clinically burdensome.

81-86	5	15.6
<b>Total</b>	<b>32</b>	<b>100</b>

**TABLE 2. COMPARISON OF OPERATIVE TIME AND BLOOD LOSS**

Parameter	HRA (n=17)	THA (n=13)	p-value
Mean Operative Time (min)	59.7 ± 7.6	91.3 ± 12.2	<0.001*
Mean Blood Loss (ml)	323.5 ± 85	490 ± 124.2	<0.001*

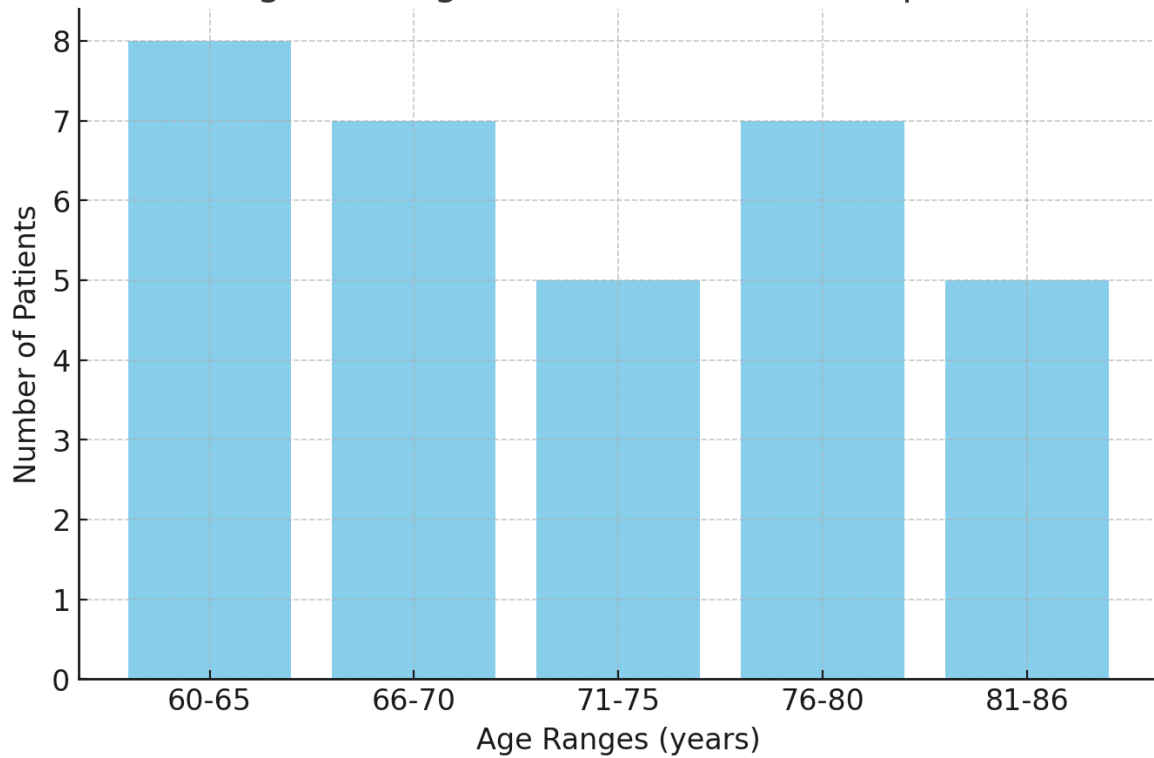
\*Statistically significant (p<0.05)

**Table 3. HARRIS hip score (hhs) at final follow-up (6 months)**

HHS Grade	HRA (n=17), %	THA (n=13), %
Excellent	70.6	78.6
Good	23.5	14.3
Fair	5.9	7.1
Poor	0	0

**REPRESENTATIVE FIGURES**

**Figure 1: Age Distribution of Participants**



**Figure 1. Age Distribution of Participants**

This bar chart illustrates the distribution of participants across different age ranges.

Figure 2: Comparative Blood Loss in HRA vs. THA

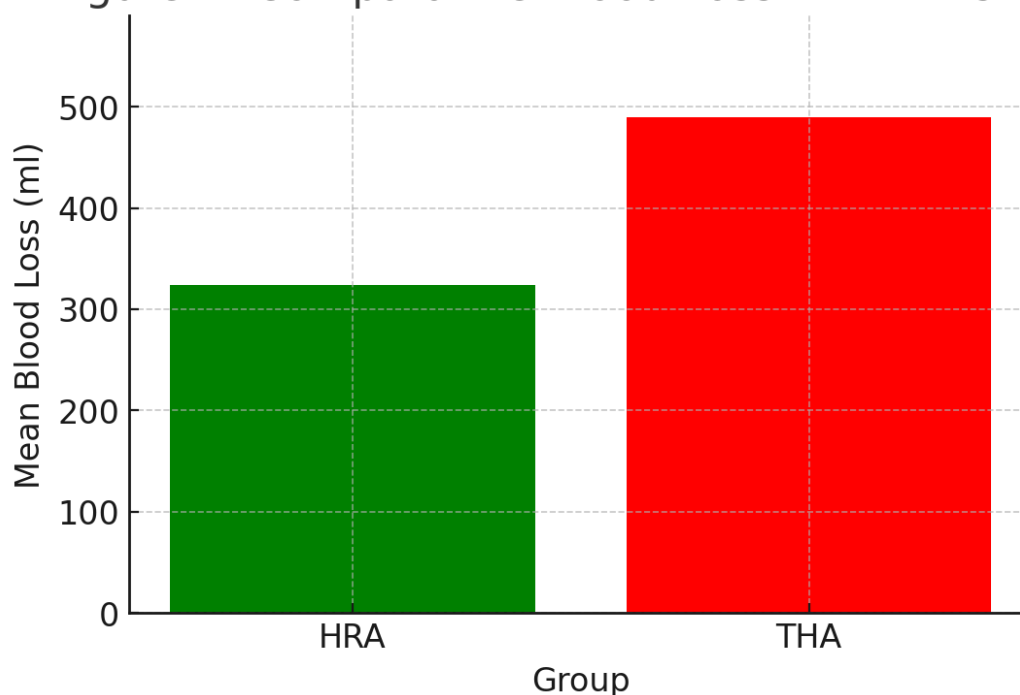


Figure 2. Comparative Blood Loss in HRA vs. THA

This bar chart compares the mean blood loss between the HRA and THA groups, highlighting significant differences in blood loss during surgery.

## DISCUSSION

Optimal treatment for displaced femoral neck fractures in the elderly remains a point of debate. Although some practitioners advocate hemiarthroplasty for its simpler technique, reduced operative duration, and minimal blood loss, others favor total hip arthroplasty for its potential to restore a more natural joint mechanism, potentially leading to better function and range of motion in active elderly individuals [9,10]. The present study found that while operative time and blood loss were significantly higher in the THA group, both procedures led to predominantly excellent or good Harris Hip Scores at six months, consistent with previous literature emphasizing the overall success of arthroplasty in this demographic [11].

Our findings align with those of authors who reported decreased surgical morbidity in hemiarthroplasty; however, they also echo the viewpoint that total hip replacement may confer improved functional outcomes and quality of life, particularly for patients who are medically fit and have higher demands [12,13]. Although earlier research occasionally raised concerns over an elevated risk of postoperative dislocation with THA, we identified only one such instance of dislocation in our cohort. This might reflect improvements in surgical technique, implant design, and postoperative rehabilitation protocols that reduce the incidence of instability [14].

Notably, the single mortality in the THA cohort highlights the intricate balance between the potential benefits of total hip replacement and the associated

perioperative risks, especially in a population often presenting with comorbidities such as hypertension, diabetes, or anemia [15]. In contrast, the HRA approach demonstrated a slightly lower complication profile overall, though the difference did not reach statistical significance beyond operative time and blood loss. Early mobilization, meticulous surgical technique, and careful patient selection were likely contributory factors to the low complication rates observed in both groups.

The comparable Harris Hip Scores between the two modalities suggest that the primary drivers of success—pain relief, restoration of ambulation, and overall satisfaction—can be achieved through either approach, provided that patients are appropriately chosen and rehabilitation is effectively managed [9,12]. This underscores the importance of individualized treatment planning that considers patient-specific elements, including biological age, comorbidities, preinjury activity level, and bone quality.

In summation, our study corroborates the perspective that both hemiarthroplasty and total hip arthroplasty are viable options for managing displaced femoral neck fractures in the elderly, with differing risk-benefit profiles. THA may be advantageous for more active, healthier seniors seeking optimized range of motion, while HRA remains a prudent choice in those with lower functional demands or significant comorbidities. Future randomized, larger-scale studies may help refine patient selection criteria and further validate our observations [14,15].

## CONCLUSION

In this prospective study comparing uncemented modular bipolar hemiarthroplasty and uncemented total hip arthroplasty in elderly patients with displaced femoral neck fractures, both procedures yielded satisfactory functional outcomes at 6-month follow-up. While total hip arthroplasty took longer operative times and resulted in higher intraoperative blood loss, it conferred excellent functional recovery in a majority of cases. Hemiarthroplasty remained a reliable and less resource-intensive option, particularly for patients with significant comorbidities. Selecting the optimal procedure requires patient-centered decision-making, balancing the individual's overall health status and activity expectations with the risk profile of each surgical approach.

## REFERRNCES

- Raja, B. S., Gowda, A. K., Singh, S., Ansari, S., Kalia, R. B., & Paul, S. (2022). Comparison of functional outcomes and complications of cemented vs uncemented total hip arthroplasty in the elderly neck of femur fracture patients: a systematic review and meta-analysis. *Journal of Clinical Orthopaedics and Trauma*, 29, 101876.
- Li, N., Zhong, L., Wang, C., Xu, M., & Li, W. (2020). Cemented versus uncemented hemi-arthroplasty for femoral neck fractures in elderly patients: a systematic review and meta-analysis of randomized controlled trials. *Medicine*, 99(8), e19039.
- DeAngelis, J. P., Ademi, A., Staff, I., & Lewis, C. G. (2012). Cemented versus uncemented hemiarthroplasty for displaced femoral neck fractures: a prospective randomized trial with early follow-up. *Journal of orthopaedic trauma*, 26(3), 135-140.
- Barışhan, F. C., Akesen, B., Atıcı, T., Durak, K., & Bilgen, M. S. (2018). Comparison of hemiarthroplasty and total hip arthroplasty in elderly patients with displaced femoral neck fractures. *Journal of International Medical Research*, 46(7), 2717-2730.
- Wu, X., Wang, Y., Sun, W., & Tan, M. (2021). Cemented and uncemented hemiarthroplasty for femoral neck fracture in elderly patients: a systematic review and meta-analysis. *Aging Clinical and Experimental Research*, 33, 2087-2111.
- Li, L., Zhao, X., Yang, X., Yang, L., Xing, F., & Tang, X. (2021). Cemented versus uncemented hemiarthroplasty for the management of femoral neck fractures in the elderly: a meta-analysis and systematic review. *Archives of Orthopaedic and Trauma Surgery*, 141, 1043-1055.
- Lewis, D. P., Wæver, D., Thorninger, R., & Donnelly, W. J. (2019). Hemiarthroplasty vs total hip arthroplasty for the management of displaced neck of femur fractures: a systematic review and meta-analysis. *The Journal of arthroplasty*, 34(8), 1837-1843.
- Kong, X. (2020). Meta-analysis of the effect of cemented and uncemented hemiarthroplasty on displaced femoral neck fracture in the elderly. *Experimental and Therapeutic Medicine*, 20(3), 2173-2183.
- Li, T., Zhuang, Q., Weng, X., Zhou, L., & Bian, Y. (2013). Cemented versus uncemented hemiarthroplasty for femoral neck fractures in elderly patients: a meta-analysis. *PloS one*, 8(7), e68903.
- Kumar, P., Rajnish, R. K., Neradi, D., Kumar, V., Agarwal, S., & Aggarwal, S. (2019). Hemiarthroplasty for neck of femur fractures: to cement or not? A systematic review of literature and meta-analysis. *European Journal of Orthopaedic Surgery & Traumatology*, 29, 731-746.
- Ning, G. Z., Li, Y. L., Wu, Q., Feng, S. Q., Li, Y., & Wu, Q. L. (2014). Cemented versus uncemented hemiarthroplasty for displaced femoral neck fractures: an updated meta-analysis. *European Journal of Orthopaedic Surgery & Traumatology*, 24, 7-14.
- Ravi, B., Pincus, D., Khan, H., Wasserstein, D., Jenkinson, R., & Kreder, H. J. (2019). Comparing complications and costs of total hip arthroplasty and hemiarthroplasty for femoral neck fractures: a propensity score-matched, population-based study. *JBJS*, 101(7), 572-579.
- Samahen, M., Mohammad, M., Salzman, M., & Ramadanov, N. (2025). The Health-Related Quality of Life for Cemented Versus Uncemented Hemiarthroplasty in Elderly Patients With Femoral Neck Fractures: A Systematic Review and Meta-Analysis of Randomized Controlled Trials. *Orthopaedic Surgery*, 17(2), 361-372.
- Rashid, A., & Ahmed, S. (2021). Evaluation and Outcome Cemented Versus Uncemented Hemiarthroplasty of Femoral Neck Fractures: A Prospective Study Tertiary Level Hospital in Bangladesh. *Saudi J Biomed Res*, 6(8), 213-220.
- Lin, F. F., Chen, Y. F., Chen, B., Lin, C. H., & Zheng, K. (2019). Cemented versus uncemented hemiarthroplasty for displaced femoral neck fractures: A meta-analysis of randomized controlled trails. *Medicine*, 98(8), e14634.